

Endorsed by



Royal College of Paediatrics
and Child Health



College of Emergency
Medicine

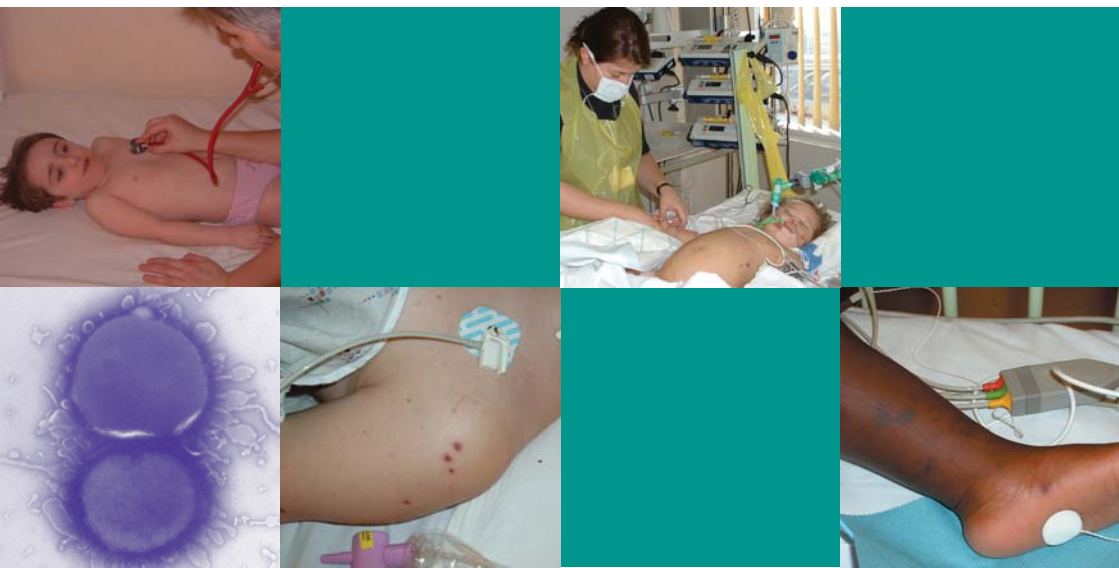Meningitis 
Research Foundation

Lessons from research for doctors in training

by Dr Nelly Ninis, St Mary's Hospital, London; Dr Simon Nadel,
St Mary's Hospital, London; Linda Glennie, Meningitis Research Foundation

Recognition and early management of
meningococcal disease in children and young people

Second Edition



This is an educational resource. It is not an evidence-based guideline on the management of meningococcal disease in children.

The handbook uses individual case histories as a basis for group discussion and learning. The clinical management points are based on the good practice guide "Early Management of Meningococcal Disease in Children" developed by St Mary's Hospital, London and produced by Meningitis Research Foundation.

Contents

SECTION 1	Introduction	2-3
SECTION 2	Clinical case histories: discussion and learning points	4-41
SECTION 3	Background to the Disease	42
	■ Disease burden	42
	■ Characteristics of meningococcal disease	43
	■ Disease pathway	43
	■ Clinical features of severe disease	43
SECTION 4	Making the Diagnosis	44
	A. Taking a history	44
	■ Symptoms of septicaemia	44
	■ Symptoms of meningitis	45
	B. Examining the patient	46
	■ Initial assessment of any febrile child	46
	■ Normal values of vital signs	48
	■ Clinical signs of septicaemic shock	49
	■ Clinical signs of meningitis	49
	■ Clinical signs of raised intracranial pressure	50
	■ The rash	51
	C. Investigation	56
	■ Initial laboratory assessment	56
	■ Lumbar puncture	57
	D. Glasgow Meningococcal Septicaemia Prognostic Score	58
	E. Pitfalls in diagnosis	59
SECTION 5	Pathophysiology and Principles of Management	64
	■ Clinical pathophysiology of septicaemia	65
	● Increased vascular permeability	
	● Myocardial dysfunction	
	● Disseminated intravascular coagulation	
	■ Specific organ dysfunction in shock	67
	■ Clinical pathophysiology of meningitis	68
	■ Management of septicaemia and meningitis	68
	■ Principles of management of septicaemia with shock	69
	■ Principles of management of meningitis with raised intracranial pressure	70
	■ Public health	71
SECTION 6	Update on development of symptoms	72
	■ Clinical features of disease	72
	■ Summary of important points	76
SECTION 7	References	77

Meningococcal disease remains an important cause of mortality in children in the UK. Two UK studies have found that aggressive treatment of severe cases can lead to an improvement in outcome^{1,2} and the 2003 American College of Critical Care Medicine consensus paper on paediatric and neonatal septic shock reported that intensive care management had reduced mortality due to septic shock in children from 97% in the 1960s to 9% 30 years later³.

Recent research by the Royal College of Paediatrics and Child Health and the meningococcal group at St Mary's Hospital, London funded by Meningitis Research Foundation, looked at health care delivery for almost 500 children with MD. During this study it was seen that a few clinical errors repeatedly led to delayed or inadequate treatment of cases with MD. Complications of meningococcal disease such as shock or raised intra-cranial pressure were often not recognised when they were present. There was also frequently a failure to appreciate how ill children were. Management of cases was often not aggressive enough given the severity of the illness and did not follow the protocol 'Early Management of Meningococcal Disease'. This was first published in 1998⁴, the fourth edition was published in Archives of Disease in Childhood 2003⁵, and the current fifth edition is due to be published there in spring 2007.

The study was published in the British Medical Journal in June 2005⁶ - 'The role of healthcare delivery in the outcome of meningococcal disease in children: case-control study of fatal and non-fatal cases'. Multivariate analysis revealed three specific management failures were independently associated with an increased risk of death. These were 1) children being managed by unsupervised junior doctors, 2) children being managed by non-paediatric trained staff and 3) a failure to use enough inotropes in septicaemic patients (this is a marker of aggressive management).

The symptoms displayed by the children in the study prior to their admission to hospital have also been analysed in collaboration with the Medical Research Council-funded Department of Primary Health Care at Oxford University, and published⁷. These data shed new light on the symptoms of meningococcal septicaemia. The data are available in this booklet in the section Update on Development of Symptoms and should make doctors aware of the importance of early signs of septicaemia and help them to make an earlier diagnosis.

The importance of this research into the management of meningococcal disease lies not only in its relevance to the correct management of meningococcal disease. The complications of MD, shock and raised intra-cranial pressure, are also seen in other life-threatening conditions, so it is extremely important for doctors in training to be aware of the early signs as prompt action saves lives.

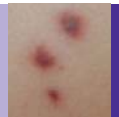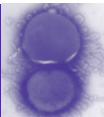
The aims of this handbook are:

- To use clinical examples to teach about the signs of septicaemia and meningitis
- To clarify the important differences between meningococcal meningitis and septicaemia
- To outline the basic management of meningococcal septicaemia and meningitis in line with the protocol '*Early Management of Meningococcal Disease in Children*'
- To describe the clinical pathophysiology of meningococcal disease.

The Clinical Case Histories section of the handbook presents cases of MD from the study, which illustrate how the early signs of meningococcal disease can be missed, and critical points in managing a case where lack of information (i.e. not measuring or monitoring vital signs), or not acting appropriately on the information available can adversely affect the outcome of the case. Each case illustrates a different learning point. Examples are taken from a range of settings to accurately reflect where children presenting with this disease were looked after. Not all children were managed by paediatricians. Non-clinically relevant details have been changed in order to preserve the anonymity of children and doctors without obscuring the clinical teaching points these cases bring to light.

On the first page of each case study, the history is recounted in the left-hand column, accompanied by questions in the middle column to guide your learning and reflection. The third column gives references to relevant sections in the handbook to test your knowledge and understanding. On the reverse of each case history is the outcome for the patient and a series of discussion and learning points. We hope that these will guide individual learners and group discussions in a clinical context. The reader is also encouraged to consult the many review articles on the subject for a more in-depth understanding of pathophysiology and management of meningococcal disease.

The material covered in this handbook has now been developed into the interactive e-learning tool, *Clinician's Guide to Recognition and Early Management of Meningococcal Disease in Children*, accessible from Meningitis Research Foundation's website www.meningitis.org and also available as a CDrom.



Section 2 | Clinical case histories

Case 1

CASE HISTORY

Child of 5 years attends Emergency Department with sudden onset fever and painful right hand.

ED triage assessment:

1)? Injury soft tissue 2) unwell, pyrexia.

Sudden onset pain in right hand. No history of trauma, she is reluctant to have it touched. She is also generally unwell. Spots erupting on arm and back. Last had Calpol 2.5 hours ago.

Observation taken: temp 39.9

2 hours later - ED doctor's assessment:

Presenting complaint: right hand swollen and painful, hand painful for 4 hours, no history of trauma. Was in contact with chickenpox 5 days ago.

On examination: temp 40.1 (55 minutes after Calpol and Brufen). Small blanching spots on body. ENT / ABDO clear. No photophobia.

Diagnosis: probable early chickenpox. Child sent home with antipyretics.

QUESTIONS

What do you think of this assessment?

Is there anything else you would want to know?

Were there abnormal symptoms or signs?

Was this a timely assessment?

What do you think of the history taking?

What do you think of this examination?

What is your differential diagnosis?

LOOK IT UP

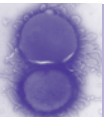
See page 48 – ‘The following clinical signs must be measured and recorded to complete a full assessment’

See page 44 – Symptoms of Septicaemia

See page 44 – Making the Diagnosis: Taking a History

See pages 46-56 – Examining the Patient

See page 61 – Making a provisional diagnosis



Section 2 | Clinical case histories

Case 1 Outcome

The child died 12 hours later of meningococcal septicaemia

DISCUSSION

ED triage assessment:

A full set of vital signs should have been measured and recorded at triage. The child may have had signs of circulatory compromise: tachycardia, tachypnoea, poor capillary refill, inadequate oxygen saturations.

No description of the spots was made, which is inadequate.

At triage, some symptoms were already abnormal, namely high fever, general unwellness, severe limb pain and new rash.

ED doctor assessment:

The time delay between triage and SHO assessment was unacceptable.

Under the Manchester Triage System a hot child with unexplained rash and severe pain is classed as very urgent - see within 10 minutes.

This was an inadequate assessment:

- Full history not taken to seek explanation of painful hand.
- Lack of response to antipyretics not taken seriously.
- Two hours since child first seen, vital signs (HR, RR, BP) had still not been measured, and there had been no assessment of peripheral perfusion, O₂ sats, conscious level or pupil size / reaction.

The girl had been in contact with chickenpox 5 days previously. Chickenpox incubation period is 10-21 days so this is an extremely unlikely diagnosis.

Although limb pain is well-established as a symptom of meningococcal septicaemia, the differential diagnosis includes osteomyelitis or septic arthritis.

It was too early in the disease process to specifically diagnose meningococcal disease while the child was in the Emergency Department. However there was sufficient cause for concern, namely an unremitting fever, a new rash, general malaise and a potential focus of infection. This child should undoubtedly have been referred to the paediatricians.

LEARNING POINTS

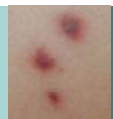
- Measure and record vital signs.
- All febrile children must be fully assessed however well they look.

- Don't forget the less common symptoms such as limb pain.

- Beware 'red herrings'.
- The early rash of meningococcal disease can be blanching in 30% of cases.
- Photophobia may be absent in a young child with meningitis and is not seen in pure septicaemia.

Conclusion

This case history illustrates how an inadequate assessment of a child allowed a serious illness to be missed.



Case 2

CASE HISTORY

Child 3 years old with short history of fever, shaking and generally unwell.

ED triage assessment:

High temperature, he looks flushed, no rash, unwell child.

Ten minutes later– ED SHO:

Febrile child, listless, irritable and drowsy.

Temp 39.7, HR 170, RR 55.

Pyrexial and drowsy: ? cause, refer to paediatric team.

Two hours later: admitted to paediatric ward.

Nursing assessment: Temp 38.4, HR 172, RR 45, BP 112/50.

Small pin prick rash on abdomen.

Ward SHO reviewed child

Sleepy but rousable, no neck stiffness or photophobia, HR 171.

No rash but few old chickenpox scars.

Chest clear.

Diagnosis: viral URTI. Child sent home.

QUESTIONS

What are the normal ranges for these vital signs? Are there any other observations you would record?

What do you think of the timing of this admission?

What do these signs tell you?

What do you think of this assessment?

Is there anything else you would want to know?

What do you think of this diagnosis? Was the appropriate action taken?

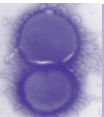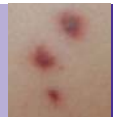
LOOK IT UP

See page 48 Table – Normal Values of Vital Signs
See page 46 – Initial Assessment of Any Febrile Child

See page 49 – Clinical Signs of Septicaemic Shock
See pages 51-56 – The Rash

See pages 46-56 – Examining the Patient
See page 56 – Initial Laboratory Assessment

See page 63 – Does your diagnosis make sense?



Section 2 | Clinical case histories

Case 2 Outcome

The child re-presented 12 hours later in uncompensated shock, with a widespread rash and died despite full resuscitation.

DISCUSSION

Triage assessment:

Appropriate in that this boy was given high priority to see the doctor.

ED SHO assessment:

Abnormal vital signs were noted and need to refer to paediatricians identified. However, a full assessment would have included saturation monitoring, capillary refill time (CRT), blood pressure and assessment of pupil size and reaction.

Long delay between Emergency Department and paediatric ward not explained in clinical notes. Such delays are totally unacceptable. If you assess a sick child and decide they need further assessment, it is your responsibility to ensure this happens speedily.

Paediatric ward triage assessment:

The vital signs on admission remained abnormal 2 hours after they were first recorded, indicating a problem. This is what early shock with cardio-vascular compensation looks like.

Although temperature dropped slightly, the child was still tachycardic, tachypnoeic. Drop in temperature not necessarily inconsistent with serious bacterial infection.

Paediatric SHO assessment:

A new pinprick rash was documented on the ward but was not taken seriously.

Totally inadequate assessment. Still no assessment of peripheral perfusion. This doctor was looking for meningitis and missed the early signs of septicaemia.

At this stage full laboratory investigations should have been done.

To confirm presence of shock, base excess (venous blood gas) should have been measured and urine output monitored.

Diagnosis:

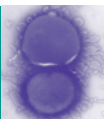
Very little evidence to support a diagnosis of viral URTI. Child was feverish and lethargic, but chest was clear, and no record of mucus, cough, sore throat, otitis media.

LEARNING POINTS

- Children with septicaemia often have rigors.
- Children in early stages of septicaemia may look reasonably well and remain relatively alert.
- If you assess a sick child and decide they need further assessment, it is your responsibility to ensure this happens speedily.
- Isolated pinprick spots may appear where the rash is mainly maculopapular so it is important to search the whole body for small petechiae, especially in a febrile child with no focal cause. The early rash in meningococcal disease can be very diverse in appearance.
- The septicaemic rash does not necessarily develop at the same rate as the septicaemia. Always examine the child for the clinical signs of shock.
- If an experienced nurse is concerned about a child then you should be too. Take note.
- Children with signs of shock require assessment by a senior paediatrician.
- Neck stiffness and photophobia are uncommon in a young child even if they have meningitis and their absence should not be reassuring.

Conclusion

In this case history, some clinical assessment was made. But the significance of the persistently abnormal vital signs was not understood and therefore not acted on. The doctor was confusing meningitis and septicaemia: looked for neck stiffness and photophobia, and finding no signs of meningitis, dismissed signs of septicaemia.



Case 3

CASE HISTORY

2.5 year old boy admitted with purpura and fever.

Paediatric assessment:

Temp 39.3, Pulse 134, RR 40, CRT 6 seconds, BP unrecordable, femoral pulses present but weak.

Cyanosed, saturation 75% in air. Widespread creps.

GCS 9/15, Neck stiffness+

Purpuric rash on chest.

Bloods sent for FBC, clotting, U&E, and culture.

Diagnosis: Meningococcal meningitis.

Treatment: Antibiotics intravenously.

Fluids 40 ml/kg colloid in 2 boluses and 10 ml/kg crystalloid over 1 hour, then maintenance fluids.

Some improvement of CRT so left on the ward.

Two hours after admission:

P178, BP 112/60 RR 46.

Increasing rash, drowsy, some response to parents.

No urine output.

Results:

WCC 3.2, INR 2.2, Hb 9.5, Plt 60.

Na 132, K 3.0, Urea 8.3, Creatinine 100

Chest X-ray shows pulmonary oedema.

Furosemide given and fluids slowed down. The child has had a total of 80 ml/kg by now.

SHO review: very fast tachycardia, ? need blood gas, ? needs LP.

Six hours after admission:

HR 194, not recognising parents. Doctor reviewed child, advised that Mannitol infusion be considered if further decrease CNS.

QUESTIONS

How would you interpret these signs?

What is the normal value for oxygen saturation in air?

What does purpuric rash suggest?

What do you think of these investigations? Is there anything else you would want to know?

Meningitis or septicaemia?

What do you think of the treatment given?

What would you do now?

What is this child's prognosis?

Why has pulmonary oedema developed?
How would you manage it?

What do you think of this treatment?

Is there any contraindication to a lumbar puncture in this child?

Why is this child confused?
Why is Mannitol inappropriate in this situation?

LOOK IT UP

See page 48 Table – Normal Values of Vital Signs
See page 46 – Initial Assessment of Any Febrile Child
See page 47 Box – Haemorrhagic Rashes

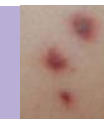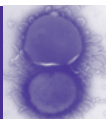
See page 56 – Initial Laboratory Assessment
See page 43 Disease Pathway & pages 49-50 – Clinical Signs of Septicaemic Shock & Clinical Signs of Meningitis

See page 69 – Principles of Management of Septicaemia with Shock & protocol: Early Management of Meningococcal Disease in Children (*inside back cover*)

See page 43 – Clinical Features of Severe Disease
See page 65 – Increased Vascular Permeability
See pages 69-70 – Principles of Management of Septicaemia with Shock
See protocol Early Management of Meningococcal Disease in Children (*inside back cover*)

See page 58 – Contraindications to Lumbar Puncture

See page 67 – Specific Organ Dysfunction In Shock
See protocol Early Management of Meningococcal Disease in Children (*inside back cover*)



Case 3 Outcome

Six hours after admission, child had a cardiac arrest and died.

DISCUSSION

Paediatric ward assessment:

Although there was mild meningism the predominant clinical picture was one of advanced shock. Paediatric intensive care should have been called immediately.

Given evidence of shock, further investigations were needed: venous blood gas, biochemistry, glucose and blood for meningococcal PCR should have been done.

Treatment:

The initial bolus of fluid and administration of intravenous antibiotics were appropriate, but the treatment was too slow. Improvement in CRT alone did not mean that shock had been reversed. The continuing presence of shock after 50ml/kg showed that the child urgently required intensive care for early elective intubation, ventilation and further aggressive resuscitation.

The pulmonary oedema is the result of advanced capillary leak. The treatment is to ventilate the child, not further deplete the intravascular volume with diuretics.

Results:

Blood gas should have been done on admission to see extent of the metabolic acidosis.

There was a significant coagulopathy which needed treatment with fresh frozen plasma.

The raised urea reflects inadequate renal perfusion secondary to intravascular hypovolaemia caused by capillary leak syndrome.

There are at least three indicators of severe disease on admission: hypotension, widespread purpura and low white cell count.

SHO review:

This SHO did not understand the illness. The very fast tachycardia indicated very advanced shock. A lumbar puncture should not even have been considered. The child's deteriorating neurological state was a pre-terminal sign of shock.


A mannitol infusion was considered as the doctor was confused as to the cause of the neurological depression.

LEARNING POINTS

- Meningococcal septicaemia with shock is a medical emergency.
- In meningococcal disease, extensive purpura are indicative of septicaemia with coagulopathy. It is very rare for this to be accompanied by raised intracranial pressure.
- When signs of established shock are present, it is essential that early aggressive management is instituted, and protocol followed with help from experts in PICU used to dealing with children in multi-organ failure.
- If features of severe disease are present (see page 43) then seek expert help urgently.
- Mannitol is used for raised intracranial pressure associated with meningitis. It is not used for septicaemia/shock.

Conclusion

This case history clearly demonstrates the importance of understanding the difference between septicaemia and meningitis, and shows how children with advanced disease need expert care.



Case 4

CASE HISTORY

15 year old boy non-specifically unwell for a day. Woke with a widespread purpuric rash and taken straight to hospital.

ED assessment:

Temp 39.0, HR 120, RR 20, BP 90/60.
Alert no meningism; purpuric rash spreading.

Diagnosis: meningococcal septicaemia.

Bloods sent for FBC, glucose, biochemistry, U&E, clotting.

Results of investigations:

Hb 12.4, WCC 4.1, Platelets 48.
Na 136, K 3.5, urea 6.2, creatinine 138.
PT (prothrombin time) >180, APTT (activated partial thromboplastin time) >240, INR 12.

Please see chart on following pages for subsequent management and clinical course.

7.5 hours:

Formal referral to PICU; telephone advice given to start aggressive resuscitation as per protocol, Early Management of Meningococcal Disease in Children.

8 hours:

CRT is 7 seconds. A venous gas is done: pH 7.10, PCO₂ 5.16, PO₂ 14.5, HCO₃ 11.9, Base excess -17.

QUESTIONS

How would you interpret these signs?
What other clinical signs are important to record?

Are there any other investigations you would undertake?

What is causing the renal impairment?
How would you interpret these results?

What test would help you establish the degree of shock?

What is this boy's prognosis?

From the chart comment on the overall fluid management.
Does this patient's good conscious level rule out shock?
Is there any contraindication to the lumbar puncture done at hour 2?
From the chart explain the significance of the fall in blood pressure at hour 5.
How would you manage this?

How would you interpret this gas?

LOOK IT UP

See page 48 – Normal Values of Vital Signs
See page 46 – Initial Assessment of Any Febrile Child

See page 56 – Initial Laboratory Assessment

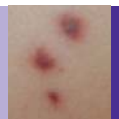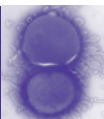
See Section 5 – Pathophysiology
See Section 5 – Pathophysiology

See page 49 – Clinical Signs of Septicaemic Shock

See page 43 – Clinical Features of Severe Disease

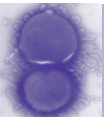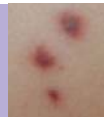
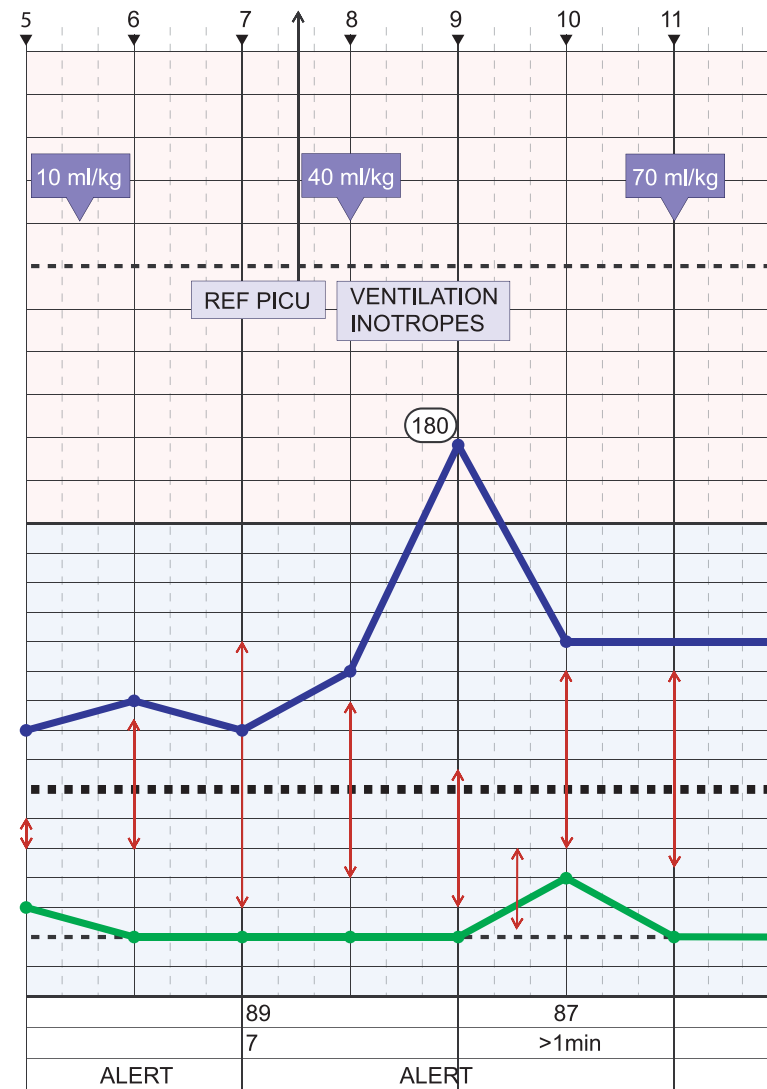
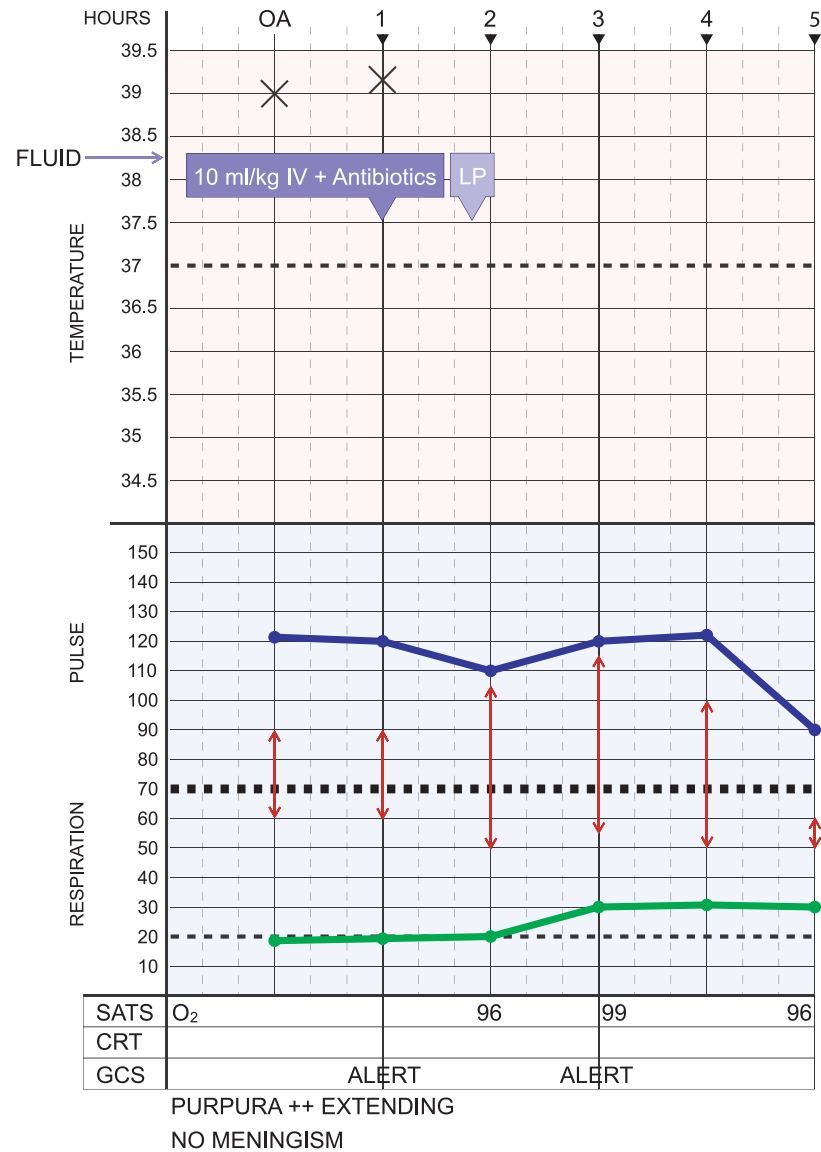
See pages 69-70 – Principles of Management of Septicaemia with Shock
See page 65 – Increased Vascular Permeability
See page 58 – Contraindications to Lumbar Puncture
See Section 5 – Pathophysiology
See protocol Early Management of Meningococcal Disease in Children (*inside back cover*)

See pages 56-57 – Initial Laboratory Assessment



Section 2 | Clinical case histories

CASE 4 CHART



Case 4 Outcome

At 7.5 hours after admission a paediatric intensive care unit was called for advice. As a result, elective intubation, ventilation and aggressive fluid management commenced. Unfortunately these measures were started too late and the patient had a cardiac arrest 3 hours later.

DISCUSSION

ED assessment:

This boy presented with meningococcal septicaemia and shock. The initial medical assessment did not record the peripheral perfusion and oxygen saturation.

The results show that the patient had a low white cell count, which is a marker of severe disease. There was also laboratory evidence of disseminated intravascular coagulation which should have been treated immediately with fresh frozen plasma and then monitored closely. The raised urea and creatinine were the result of intravascular hypovolaemia secondary to capillary leak syndrome.

A venous blood gas would give a base excess which is a measure of the metabolic acidosis associated with shock.

The clinical and laboratory features indicated very severe disease.

ED management:

The fluid management was totally inadequate. Management should aim to maintain or restore circulating volume and optimise tissue perfusion. If the response to initial resuscitation is inadequate, and shock does not improve or progresses, then more than 60ml/kg may be required in the first hour. This patient had only 20 ml/kg in the first 6 hours after admission. No urine output was measured. By the time PICU help was sought, he was in de-compensated shock.

A lumbar puncture is absolutely contraindicated in the face of widespread purpura, severe coagulopathy and cardiovascular shock

Vital signs on chart. Note that the tachycardia remained well above the normal range for age throughout the day. This was the result of intravascular hypovolaemia. The patient should have been catheterised to monitor the urine output on an hour-by-hour basis. By hour 3 the respiratory rate had risen to 30, most likely as a result of acidosis, pulmonary oedema and hypoxia. The teenager remained alert which is often seen in septicaemia and may falsely reassure doctors as to the severity of the illness.

At hour 5 a very low blood pressure was recorded, because by this time, compensatory mechanisms were failing. Hypotension is a late and serious sign in septic shock in children and teenagers. This indicated that the patient needed much more aggressive resuscitation as per protocol, Early Management of Meningococcal Disease in Children.

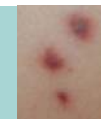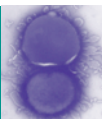
The blood gas done eventually at 8 hours shows a severe metabolic acidosis.

LEARNING POINTS

- Meningococcal septicaemia with shock is a medical emergency.
- Children who present with meningococcal septicaemia in the morning may have very advanced disease as they have many hours during the night, unobserved by their parents, in which to become ill.
- If features of severe disease are present (see page 43), then seek expert help immediately.
- Children with shock may be alert until late in the illness and this may make them look less sick than they actually are.
- Hypotension is late sign of shock in children and does not need to be present to diagnose shock.
- Children with shock need assessment by a senior paediatrician
- Refer early to a regional paediatric intensive care unit.

Conclusion

This case history shows that despite the correct diagnosis of meningococcal septicaemia being made, the resuscitation was slow and inadequate. The child remained in Accident and Emergency for 8 hours instead of being transferred to a PICU immediately. A diagnosis of meningococcal septicaemia should bring about urgent medical treatment, and expert help should be sought if there are signs of shock



Case 5

CASE HISTORY

10 month old boy. Taken to GP with h/o sudden onset of fever, vomiting and lethargy for 4 hours. Mother very anxious about child. GP referred child to walk-in clinic at hospital.

History on admission: Feverish and drowsy – sudden onset. 2 episodes of vomiting, 1 soft stool, no rash.

Assessment on admission:

Drowsy and pale, dark rings around eyes.

Temp 37.7

CVS: P 181, BP 120/52 CRT 4 secs. Child peripherally shutdown.

RS: RR 32 breathing laboured and child cyanosed.

SaO₂ 100% in oxygen.

NS: GCS10 then 9, no neck stiffness.

Fine blanching rash on abdo/chest. 1 petechial spot on abdo.

Diagnosis: meningococcal septicaemia

Action taken:

1. Immediately given antibiotics and 40 ml/kg albumin.
2. 'Crash call' put out for PICU team.
3. Full set bloods taken.

Results of investigations:

WCC 2.4, Hb 10.5, pl 70.

Glucose 3.8

Na 149, K 3.4, Ca 2.1, Mg 0.4, PO₄ 1.6, Urea 10.9, Creat 121.

HCO₃ 15, BE -7.

PT 30, APPT 75, INR 2.5.

Taken to PICU. Still shocked after 40ml/kg. Electively intubated and ventilated, Adrenaline started. Commenced correction of acidosis, K and Mg.

Extensive purpuric rash developed.

PICU consultant called in to supervise care.

QUESTIONS

What might sudden onset of illness in an otherwise well child suggest?

What do you think of this assessment?
What do these signs tell you?

How would you interpret the normal blood pressure in the context of other observations?
When conscious level is depressed and/or falling, is severity of disease likely to be worse when signs of meningitis are present, or when they are absent?

Does the very scanty rash rule out meningococcal disease?

What do you think of this course of action?

What do you think of these results?

Is there evidence of organ failure?

LOOK IT UP

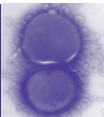
See pages 44-45 – Taking a History: Symptoms of Septicaemia

See pages 46-47 – Initial Assessment of Any Febrile Child
See page 49 – Clinical Signs of Septicaemic Shock
See page 65 – Increased Vascular Permeability
See page 43 – Clinical Features of Severe Disease

See pages 51-56 – The Rash & page 62 – How much rash do you need to diagnose meningococcal disease?

See protocol Early Management of Meningococcal Disease in Children (*inside back cover*)

See page 43 – Clinical Features of Severe Disease
See pages 56-57 – Initial Laboratory Assessment
See page 67 – Specific Organ Dysfunction In Shock



Case 5 Outcome

Subsequent PICU care (summary): Severe respiratory failure with pleural effusion: ventilated for total of 3 weeks. High dose inotropes required for several days. Severe coagulopathy – treated with fresh frozen plasma and cryoprecipitate. Renal replacement therapy needed. Peritoneal dialysis later that evening for fluid overload and renal failure – progressed to haemofiltration after several days. 3 weeks PICU, in hospital 2 months.

DISCUSSION

Sudden onset of illness in otherwise well child. Only a short history taken but child clearly recognised to be very sick and treatment started.

Assessment very thorough and entirely appropriate. Evidence of shock. Tachycardia, cool peripheries. Note normal blood pressure which in association with signs of shock indicates cardiac compensation.

Child has evidence of respiratory decompensation secondary to acidosis, hypoxia and capillary leak syndrome.

Depressed or falling conscious level must always be taken seriously, but it may occur quite early in meningitis. Depressed or falling conscious level in a patient with septicaemia, in the absence of signs of meningitis, indicates very advanced shock.

The rash was not dramatic on admission. There was only one non-blanching spot. This shows how the typical haemorrhagic rash may only appear once the child is very ill. Do not be reassured if a child has only a scanty rash, you must try to determine how advanced the underlying septicaemia is.

The results showed a low white cell count, falling platelets, coagulopathy and rising urea and creatinine. These are all features of severe disease. Laboratory results outside normal ranges. There were signs of multiple organ failure.

The severity of the child's illness was appreciated immediately and aggressive resuscitation commenced. Senior help was called for and the child was admitted to an appropriate intensive care unit.

Once on PICU the aggressive management was continued following the early management protocol. Senior PICU help was sought to ensure this child had one to one medical attention whilst being stabilised. The typical rash of meningococcal septicaemia was by then apparent. Multiorgan failure was managed in PICU.

LEARNING POINTS

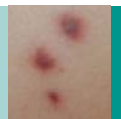
- Febrile illness of sudden onset = classic picture of meningococcal disease, mainly affecting well children. However, respiratory illnesses, particularly flu, may predispose to meningococcal disease. The less typical picture is of initially trivial symptoms suddenly becoming more serious with a high fever and other symptoms.
- Always take a parent's anxiety very seriously.
- **Meningococcal septicaemia is a medical emergency.**
- Falling conscious level in a shocked child is a poor prognostic sign.

- Isolated pinprick spots may appear where the rash is mainly blanching so it is important to search the whole body for small petechiae.
- Underlying disease may be very advanced by the time a rash appears. The rapidly evolving haemorrhagic 'text book' rash may be a very late sign. It may be too late to save the child's life by the time this rash is seen. It is important to look for physical signs of serious systemic illness even if there is no rash or an unimpressive rash.

- Once shock is advanced, it can only be reversed by aggressive resuscitation and management of complications in intensive care.

Conclusion

Children with severe septicaemia and multiorgan failure have a high risk of mortality especially if they are under 1 year of age. In this case all the signs of severe illness were recognised immediately and acted on appropriately. It is likely that without such rapid medical attention this child would have died.



Case 6

CASE HISTORY

14 year old girl admitted to hospital with 24 hour history of fever, increasing headache associated with 6 episodes of vomiting in evening. She has developed photophobia. Also feels generally unwell with myalgia.

GP visited and gave IM penicillin as meningitis considered the most likely diagnosis. GP arranged transfer to hospital by 999 ambulance.

SHO assessment on arrival:

Responsive, mild photophobia, no neck stiffness.
Temperature 39.7.
CVS: Pulse 85 regular, BP 115/75.
Heart sounds normal.
Chest clear, abdomen normal.
Pale macular rash over trunk, no purpura.

NS: Glasgow coma score 15/15.
Full power in arms and legs – all movements.
Cranial nerves intact, no papilloedema.

Differential diagnosis made of meningitis or viral illness. Given intravenous antibiotics immediately and blood tests sent.

1 hour later (registrar review):

Conscious level has deteriorated over the past hour. Now no communication, eyes open. Neck stiffness+++

BP 150/90, HR 90.
? to CT ? to do lumbar puncture.

Lumbar puncture is performed. CSF is cloudy and under very high pressure. Patient deteriorates rapidly with falling conscious level, decrease in respiratory effort.

Patient is intubated and ventilated and taken to intensive care

QUESTIONS

What diagnosis does this history of symptoms suggest?

What do you think of the action taken by the GP?

What do you think of this assessment? What other observations would have completed the assessment?

Does the blanching rash rule out meningococcal disease?

Does the absence of papilloedema rule out meningitis?

Should antibiotics be delayed until a more definitive diagnosis made? Should adjunctive treatment be considered here?

What has occurred?

What treatment does the patient need now?

Are there any contraindications to LP?

LOOK IT UP

See pages 44-46 – Taking a History

See page 46 – Initial Assessment of Any Febrile Child

See pages 51-56 – The Rash & page 62 – How much rash do you need to diagnose meningococcal disease?

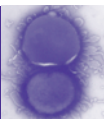
See pages 50-51 – Clinical Signs of Raised Intracranial Pressure

See page 68 – Management of Septicaemia and Meningitis

See pages 50-51 – Clinical Signs of Raised Intracranial Pressure

See protocol Early Management of Meningococcal Disease in Children (*inside back cover*)

See page 58 – Contraindications to Lumbar Puncture



Section 2 | Clinical case histories

Case 6 Outcome

The patient did not recover and was found to be brain stem dead.

DISCUSSION

This history is typical of meningitis. The patient is generally unwell with fever and myalgia but has features of CNS infection with headache, vomiting and photophobia.

Appropriate treatment from the GP.

SHO assessment:

This is a good assessment. The conscious level was recorded and signs of raised intracranial pressure looked for, however pupillary responses and size should also have been recorded. The SHO suspected meningitis, which was reasonable, but peripheral perfusion and oxygenation should also have been assessed.

The rash is non-specific.

Immediate administration of IV antibiotics was appropriate. Adjunctive dexamethasone should be considered before, with or within 4 hours of the first dose of antibiotics, if there are no signs of septic shock.

Registrar review:

LP should only be undertaken once it has been decided that the patient is stable enough to undergo this procedure.

There was a dramatic change in the patient's condition. The patient developed features of raised intracranial pressure. The patient urgently needed treatment to reduce the intracranial pressure.

With the dramatic change in conscious level it would have been dangerous to take the patient to the scanner without securing the airway. LP was contraindicated.

The patient unfortunately coned whilst having the lumbar puncture. All efforts to resuscitate the patient after this were unsuccessful.

LEARNING POINTS


- Always look for signs of raised intracranial pressure (RICP) in all patients with evidence of meningitis.
- In cases of pure meningitis, the rash is more often scanty, absent or atypical than in septicaemia or meningococcal disease with mixed presentation.
- Papilloedema does not have to be present to diagnose RICP, it is a late sign.

- Antibiotics should be given immediately if the diagnosis of meningitis is included in the differential. Consider steroids when there are no signs of septic shock.

- **Raised intracranial pressure is a medical emergency.**
- Call for senior help and Paediatric Intensive Care immediately if there are signs of RICP.
- Lumbar puncture is strictly contraindicated when there is RICP, e.g. if the conscious level is deteriorating and the blood pressure is rising.

Conclusion

All patients with meningitis must have clinical signs of raised intracranial pressure looked for and always rechecked prior to doing an LP. Beware the patient who deteriorates after admission. If in doubt delay lumbar puncture until senior advice can be sought.



Case 7

CASE HISTORY

15 year old boy, 30 hours of flu-like illness. On day of presentation his mother found him febrile and confused in bed.

Assessment on admission 07:30:

Temp 38.2.
HR 103, BP 148/102
Incoherent and behaving inappropriately.
Some neck stiffness, Kernig's sign negative.
Movements almost decerebrate.
Purpuric rash noted.

Diagnosis: meningococcal meningitis
Bloods sent for FBC, clotting, U&E, and culture

Action taken:

Given intravenous antibiotics.
Admitted to ward.

On examination on ward:

Agitated, disorientated and confused with fluctuating conscious level. He had developed a convergent squint.

Sent to radiology for CT scan.

Investigations:

Hb 14, WCC 15.2, pl 190.
Urea 4.7, creatinine 54.
Na 140, K 4.2, Bicarbonate 24.
INR 1.0, PTTR 1.2.

CT scan showed no signs of raised intracranial pressure.

10:30: The patient's conscious level fell to 8/15 and then he suffered a respiratory arrest. The BP was 225/115. He had no respiratory effort and so was intubated and ventilated.
He was turned onto his side for a lumbar puncture, which was performed. He suffered a sudden onset of bradycardia and hypotension with desaturation.

QUESTIONS

In teenagers, CNS symptoms and confusion are sometimes misinterpreted. What mistaken diagnosis might be reached?

What do these observations indicate?

What do you think of this assessment? What further assessment should be made?

What do you think of this treatment?

What do you think of the action taken?

What needs to be done now?

Are there signs of co-existing shock or coagulopathy?

Is CT scanning sensitive to RICP?

Are there any contraindications to LP in this situation? Is LP necessary?

LOOK IT UP

See pages 49-50 – Clinical Signs of Meningitis

See pages 49-51 – Clinical Signs of Meningitis & Clinical Signs of Raised Intracranial Pressure

See page 46 – Initial Assessment of Any Febrile Child.

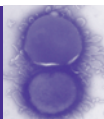
See page 68 – Management of Septicaemia and Meningitis
See pages 70-71 – Principles of Management of Meningitis with Raised Intracranial Pressure

See protocol Early Management of Meningococcal Disease in Children (*inside back cover*)

See page 49 – Clinical Signs of Septicaemic Shock, and page 67 – Specific Organ Dysfunction in Shock

See pages 50-51 – Clinical Signs of Raised Intracranial Pressure

See page 58 – Contraindications to Lumbar Puncture



Case 7 Outcome

The pupils were noted to be fixed and dilated when examined a few hours later. The following day brain death tests were performed and the patient was declared brain dead.

DISCUSSION

Assessment on admission:

There were signs of raised intracranial pressure (RICP) present on admission. There was systemic hypertension, depressed conscious level and abnormal movements.

There should have been an assessment of pupil size and reactivity and examination of the fundi.

Action taken:

Antibiotics were essential but the patient should also have been given steroids and mannitol immediately and electively intubated and ventilated to try and reduce the RICP. **This patient urgently needed expert treatment in intensive care.**

Investigations:

Note that even in patients with severe meningitis the investigations remain relatively normal. There was no acidosis, coagulopathy, renal dysfunction.

10:30:

There were clear clinical signs that the patient's condition was deteriorating and dangerously unstable and the RICP needed immediate action. CT scanning and waiting for test results resulted in 3 hours delay and was unacceptable.

The raised intracranial pressure was severe leading to respiratory arrest. There is grossly elevated systemic hypertension.


The patient coned. Clearly he had advanced disease on presentation but no efforts were made prior to his respiratory arrest to stabilise him and reduce the raised intracranial pressure. The lumbar puncture was unnecessary for initial diagnosis and totally contraindicated after his respiratory arrest.

LEARNING POINTS

- Acute confusion in a teenager may be mistaken for drug or alcohol intoxication. Meningitis and encephalitis must be included in the differential diagnosis of a teenager who is acutely confused or disruptive.
- Raised intracranial pressure is a medical emergency. **Call for senior help and Paediatric Intensive Care immediately if there are signs of RICP.**
- Ophthalmoplegia (new squint) is a further sign of raised intracranial pressure with herniation of supratentorial part of the brain through the tentorial opening. This must be acted on immediately.
- CT scanning is not a sensitive tool in detecting RICP. It is dangerous to put a child with fluctuating conscious level into the scanner without securing the airway first.
- It is crucial to look for the signs of RICP before attempting LP and defer if signs are present. Lumbar puncture is contraindicated when there are signs of RICP and neurological failure.

Conclusion

This boy presented with raised intracranial pressure which is a medical emergency. This was not appreciated. Inappropriate investigations were conducted and no emergency management of the condition was undertaken.



Section 2 | Clinical case histories

Case 8

CASE HISTORY

12 year old boy referred to hospital by his GP. He was found to be febrile & drowsy with a few non-blanching spots. The GP gave a dose of intra-muscular penicillin and sent him into hospital as an emergency.

18:00 hours ED triage:

Fever for a day, generally unwell with headache, regular paracetamol during day. No urine output since very early morning. No neck stiffness or vomiting. Temperature not coming down, new rash on back, increasingly drowsy.

Observations: temp 39.5, pulse 148, RR40, Cold hands and feet. Sats 92% in air. Conscious level is V (AVPU scale). Widespread non-blanching rash on trunk

Nursing actions: probable meningococcal disease, put out emergency call for paediatrics. High-flow oxygen started via facemask. BM done = 6.5.

18:15 hours paediatric registrar and SHO:

History taken as above; rash noted to be purpuric. Initial examination (in oxygen): airway clear, good saturations, equal breath sounds, no crepitations. Heart rate fast at 143, capillary refill time 6 seconds at feet. Heart sounds: gallop rhythm. BP 114/72. Rash is spreading, now on legs as well. Responding to voice, no neck stiffness, equal pupils. Blood gas taken to assess the degree of metabolic acidosis: pH = 7.2, BE = - 9.

Diagnosis: meningococcal septicaemia with shock.

The medical team used the Glasgow Meningococcal Septicaemia Prognostic Score to score the illness.

Given ceftriaxone and 20ml/kg bolus of albumin. Bloods taken for full blood count, glucose, electrolytes, biochemistry, clotting, blood culture, meningococcal PCR, blood gas to assess severity of metabolic acidosis.

Reviewed patient. Still shocked. Fluid bolus (20ml/kg) repeated.

19:00 hours. PICU (in same hospital) called and care taken over by intensive care team. By now patient has had 60ml/kg of albumin and shock persisting. Patient intubated and ventilated and inotropes started centrally.

QUESTIONS

What do you think of the GP's action?

What do you think of the history taken?

Are there any other observations you would record?

Has the nurse acted appropriately?

What do you think of this assessment?

How would you interpret these signs?

Were there signs of severe disease?

What GMSPS score does the patient have on admission? What is his prognosis?

Why was the patient intubated and ventilated?

LOOK IT UP

See pages 44-46 – Taking a History

See page 46 – Initial Assessment of Any Febrile Child

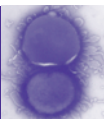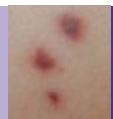
See pages 69-70 – Principles of Management of Septicaemia with Shock

See page 48 – Assessment of a Febrile Child with Suspected Meningococcal Disease
See page 49 – Clinical Signs of Septicaemic Shock

See page 43 – Clinical Features of Severe Disease

See pages 58-59 – Glasgow Meningococcal Septicaemia Prognostic Score

See pages 69-70 – Principles of Management of Septicaemia with Shock



Case 8 Outcome

The patient was ventilated for 5 days and recovered with no serious complications. He required some skin grafting for an area of skin necrosis where there had been extensive rash.

DISCUSSION

Meningococcal disease was recognised in this child by the GP, who commenced treatment with parenteral penicillin and sent the child to hospital urgently.

The history taking was thorough and relevant given the GP's actions. Oliguria identified, aiding early diagnosis of shock.

Observations were comprehensive enough to show what was wrong with this child. There were signs of circulatory insufficiency, so BP should have been taken, but nurse correctly put out a crash call and ensured that BP was measured within 15 minutes.

The nursing action was timely and appropriate. The severity of the child's condition was understood, and he was treated as a medical emergency.

The medical team completed a full assessment – thorough examination following ABC. The initial vital signs were very abnormal and remained so on repeated examination.

The assessment revealed at least 7 signs of shock: tachycardia with gallop rhythm, tachypnoea, prolonged CRP, reduced urine output, drowsiness, hypoxia (on admission), acidosis.

The medical team appreciated the patient had clinical features of severe disease: shock, absence of meningism, rapidly progressive purpuric rash, depressed conscious level. The initial laboratory investigations initiated by the medical team would have detected laboratory markers of severe disease.

They also scored the child using the GMSPS, which is validated for use in hospital when the patient presents. The score was 9, indicating serious illness.

Respiratory failure is common in shock. Capillary leak into lung parenchyma causes acute pulmonary oedema.


It was fortunate that there was a PICU in the hospital and that this team were able to take care of the child immediately. However, all local hospitals are able to stabilise a seriously ill child whilst waiting for a PICU to retrieve the child. Following the early management protocol and liaising with the PICU by telephone will ensure the correct actions are taken in the early stages of treatment.

LEARNING POINTS

- All patients in septic shock should be given high flow oxygen.
- Always repeat the vital signs when you see a patient.
- Even with prompt recognition and rapid treatment of meningococcal disease, patients may become shocked.
- Patients in shock may not respond to initial management, requiring aggressive resuscitation, inotropes and correction of biochemistry to stabilise.
- Involvement of paediatric intensive care is vital in children with septicaemic shock.

Conclusion

This case illustrates that even children with rapidly advancing illness can be treated successfully if the disease is recognised and fast, appropriate action taken.



Section 2 | Clinical case histories

Case 9

CASE HISTORY

4 year old girl brought by ambulance after a prolonged seizure that began 40 minutes earlier. Parents found her in the living room shaking all of her body and unresponsive to their voices. Immediately called 999 ambulance. The paramedic team have given diazepam rectally and she is on 100% oxygen.

Non-specifically unwell for several days with a cold and irritability. Fever for 24 hours and vomited during the day – her parents have been giving her paracetamol. She has never had fits before. No family history of seizures.

Taken immediately to ED Resuscitation: Status epilepticus ? cause – possible infection.

ED SHO assessment immediately:

Airway self-maintained but Guedal airway in situ inserted by paramedics. 100% oxygen with saturations of 100%. Air entry equal bilaterally. Well-perfused centrally. Generalised tonic clonic seizure continuing. No rashes seen.

Observations: Temp 39.5, BP 130/80 (difficult to measure), Pulse 100, RR 56. Blood sugar 7.1.

Immediate intervention:

IV access obtained X 2, bloods taken for FBC, clotting, U&E, biochemistry, culture, PCR, blood gas.

IV ceftriaxone and acyclovir commenced.

Given IV lorazepam X 2 0.1mg/kg, failed to stop seizure.

Loaded with phenytoin, 20 minutes later stopped fitting.

Further clinical assessment: Only responding to deep painful stimuli (AVPU), pupils size 7 slowly reacting, normal fundi. BP 140/85, HR 90

Diagnosis: possible meningitis or encephalitis with raised intracranial pressure.

Anaesthetic team called, child intubated and ventilated. Admitted to intensive care whilst PICU team arrives.

Results: WCC 18, Hb 9.2, Platelets 402, Na 128, K 3.3, Ur 8.0, Cr 37, bicarbonate 24, BE -1, Clotting : PT 14, APTT 32, INR 1. CRP 289.

Transferred by retrieval team to nearby tertiary PICU. Remained ventilated for 2 days on minimal settings, no inotropic support required.

Following extubation alert and appropriate. LP performed: CSF 5000 white cells predominantly polymorphs. No growth on CSF or blood. CSF PCR positive for meningococcus B. Blood cultures negative.

QUESTIONS

Appropriate initial assessment and management?

Are there any other observations you would want to record?

What do these observations indicate?

Should LP or CT scan be done to confirm the diagnosis?

What would you do now?

Are these results consistent with meningitis?

Is there any use in performing LP at this point?

LOOK IT UP

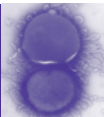
See page 79 reference 47 – CATS Clinical Guideline: Status Epilepticus. November 2005. Children's Acute Transport Service.

See page 46 – Initial Assessment of Any Febrile Child

See page 50-51 – Clinical Signs of Raised Intracranial Pressure

See page 51 – Clinical Signs of Raised Intracranial Pressure
See pages 70-71 – Principles of Management of Meningitis with Raised Intracranial Pressure

See pages 57-58 – Lumbar Puncture



Case 9 Outcome

This child did well post-extubation, was transferred back to local hospital and subsequently discharged home. Follow-up revealed a mild degree of sensorineural hearing loss in both ears requiring aids.

DISCUSSION

The child was managed well in accordance with the APLS guidelines for a seriously ill child: ABC assessment with stabilisation prior to moving onto D and E. The prolonged seizure was managed correctly following the APLS seizure protocol.

Immediate assessment was comprehensive enough to enable urgent intervention. Other observations, including pupil size and reaction, fundoscopy, peripheral perfusion and examination for neck stiffness would be helpful after the fitting stops, along with repeat of blood pressure measurement, and continued vigilance for the appearance of a rash.

After fitting stopped, RICP was correctly identified through good clinical examination, vital signs measurement and pupil assessment.

Stabilisation of the child's clinical condition was the appropriate priority, and correctly, the child did not have an LP or CT scan. LP is contraindicated in patients with depressed conscious level or RICP. RICP is a clinical diagnosis and an urgent scan would only be indicated if the child had focal signs.

RICP requires management in PICU. The aim of management is to maintain oxygenation and nutrient delivery to the brain.

The results from laboratory investigations were consistent with meningitis. In cases of meningitis without septicaemia, the base deficit is usually less negative than -5, and there is minimal derangement in coagulation. The slightly raised urea here was probably secondary to dehydration or vomiting.

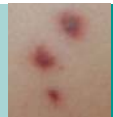
PCR on CSF samples may be positive hours or even days after antibiotics have been given. For this child, laboratory confirmation of meningitis was important for follow up care, particularly if sequelae were later to become apparent and educational support at school was needed. Confirmation of the etiology is important for public health management of contacts as well as disease surveillance.

LEARNING POINTS

- RICP is a clinical diagnosis.
- Raised intracranial pressure is a medical emergency. **Call for senior help and Paediatric Intensive Care immediately if there are signs of RICP.**
- Patients with 'pure' meningitis may have no rash at all and often will not have any signs of shock or coagulopathy.
- LP must not be performed when contra-indicated, but a delayed LP can still result in a laboratory-confirmed diagnosis.
- A laboratory-confirmed diagnosis is important for assessing the need for follow up care, for public health management of contacts, and for disease surveillance.

Conclusion

This case shows how a child with a prolonged seizure and raised intracranial pressure was safely managed using protocols and rapid admission to PICU.

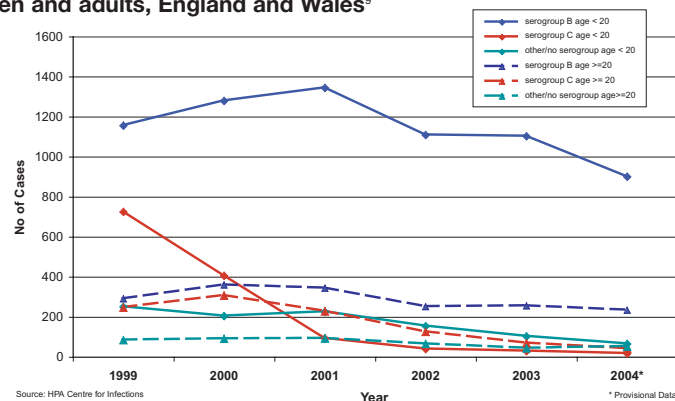


Section 3 | Background to Disease

DISEASE BURDEN

Meningococcal disease can kill in hours and takes more than one hundred lives in the UK each year⁸. It is not only associated with a significant risk of mortality, but also with long term morbidity. Those who recover may be left with disabilities that dramatically alter their lives, including amputations, scarring, sensory deficits, intellectual impairment, epilepsy, and a range of less specific cognitive and psychological disorders. The meningococcus is the main cause of bacterial meningitis in children and young adults, and a common cause of septicaemia and shock at these ages. Cases of meningococcal disease reached a 50-year peak in 1999. That year MenC vaccine was introduced and has had a tremendous impact. Cases of serogroup C meningococcal disease have dropped by over 90%⁹. However, serogroup B meningococcal disease was more common, particularly in children, even before MenC vaccine was introduced. No vaccine available can protect against most group B serotypes and sero-subtypes circulating in the UK, so serogroup B disease continues to fluctuate unchecked.

Lab-confirmed meningococcal disease, children and adults, England and Wales⁹



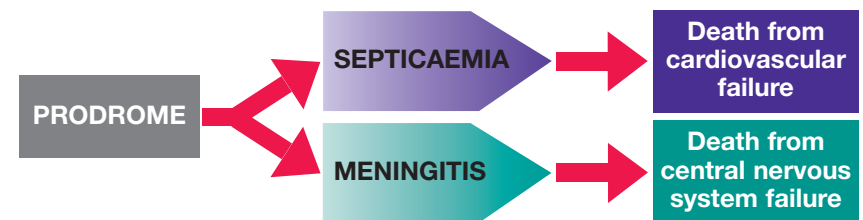
Based on lab-confirmed cases, the incidence of meningococcal disease in England and Wales in 2004 was 7.5 cases per 100,000 population aged less than 20. Enhanced Surveillance of Meningococcal Disease aims at more complete ascertainment of cases, and in 2004, identified approximately half again as many cases as were laboratory confirmed. Enhanced Surveillance currently reports¹⁰ that the rate of confirmed meningococcal disease is highest in the under-fives, particularly among infants: 52.9 cases per 100,000 <1 year of age, 18.8 cases per 100,000 aged 1-4 years. In children older than 4 years of age, the rate is 3.1 cases per 100,000. Case fatality ratios in children are highest in teenagers older than 14, followed by infants less than 1 year of age.

Cases of meningococcal disease were lower in 2004 than for many years, but for 2005 the Meningococcal Reference Unit reports an increase of 11% from the previous year¹¹. These figures are for England and Wales, but incidence rates are similar across the UK.

CHARACTERISTICS OF MENINGOCOCCAL DISEASE

The two major clinical forms of meningococcal disease are meningitis and septicaemia. Most patients will have a mixed presentation. A minority will have pure septicaemia and it is these patients who carry the worst prognosis and maximum effort must be made to identify them early¹². There are important differences in the pathophysiology of meningitis and septicaemia which underlie the clinical presentation and management of the two main forms of the condition (see Pathophysiology).

DISEASE PATHWAY

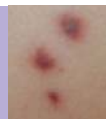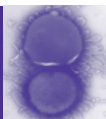


CLINICAL FEATURES OF SEVERE DISEASE

The diagram above illustrates the main causes of death from MD. In the majority of patients, one disease process predominates. Patients presenting with mixed disease will also tend, as the disease worsens, to become either profoundly septicaemic or profoundly meningitic. A few will have combined severe septicaemia with shock and severe meningitis with raised intracranial pressure and these need expert management. Patients presenting with septic shock without meningitis carry the worst prognosis^{8,13}. Although a few patients with meningitis will die from raised intracranial pressure, most deaths from MD result from shock and multi-organ failure¹⁴.

FEATURES WHICH PREDICT POOR PROGNOSIS AT THE TIME OF PRESENTATION INCLUDE:^{13,14}

- Presence of shock
- Absence of meningism
- Rapidly progressive purpuric rash
- Low peripheral white blood cell count
- Thrombocytopenia
- Markedly deranged coagulation
- Depressed conscious level



Section 4 | Making the Diagnosis

This section aims to help doctors, especially doctors in training, to avoid some of the common pitfalls in recognising and treating children with meningococcal disease. It is not a fail-safe diagnostic package: since no symptom is entirely specific to this disease, many children with the symptoms described will not have MD. We hope to prompt doctors to ask "could this be meningococcal disease?" when assessing a child in the Emergency Department or on the wards where the diagnosis is in doubt.

A. TAKING A HISTORY

Meningococcal disease is extremely unpredictable. The presentation can be very varied and patients may be difficult to differentiate from those with viral illnesses during the early stages. Most children with MD present as an acutely febrile child and may not have a rash at first.

It is important to take a detailed history and ask parents about the specific symptoms of septicaemia and meningitis. Beware of simply 'eyeballing' a child and assuming they have a trivial illness. This is how many mistakes are made. Make sure you have understood what exactly is worrying the parent and why they are seeking help at this point. Be careful if the child has had contact with a case of meningococcal disease even if they have had prophylactic antibiotics as they can still become ill. Ask about travel to sub-Saharan Africa or contact with Hajj pilgrims.^{15,16}

At the initial assessment look for signs and symptoms of septicaemia or meningitis. Some symptoms can be subtle and must be specifically asked about when taking a history.

SYMPTOMS OF SEPTICAEMIA

■ Fever

- Many children become suddenly ill with a fever: the classic picture is of a disease of rapid onset. However, some children develop septicaemia after a simple viral illness. In these cases the symptoms may be initially trivial and last for some time and then suddenly become more serious with a high fever and other symptoms of sepsis.
- A history of a fever in a child presenting afebrile is important.
- Not all children with meningococcal disease (or other serious bacterial infection) have fever¹⁷.
- A fever that subsides after antipyretics cannot be dismissed as viral in origin.
- Hypothermia, especially in infants, may also indicate serious infection.¹⁸

■ **Rigors** Children with septicaemia often have rigors¹⁹. Occasionally the shaking, if very severe may be mistaken for fitting, but children having rigors will remain conscious.

- **Aches** They usually experience very bad muscle aches and joint aches making them restless and miserable.
- **Limb pain** Isolated severe limb pain in the absence of any other physical signs in that limb is a well-established phenomenon in MD^{20,7}. The pain can be very severe and children have been mistakenly put into plaster to treat presumed fractures.
- **Gastrointestinal symptoms** Vomiting, nausea and poor appetite (poor feeding in babies) are common in septicaemia. Abdominal pain and diarrhoea (leading to faecal incontinence in some cases) are less common but well documented²¹. This can create confusion with gastro-intestinal infections.
- **Weakness** This can become profound.
- **Rash** Ask about any new rashes or marks on the child's skin that the parents may have noticed. Note that parents may not realise that the petechiae or purpura or 'bruises' on the child's skin are a rash as they associate the word 'rash' more with a pink 'measles-like' rash. They may use other words to describe the rash, for example bruise, spot, freckle, blister, stain or mark on the skin – like chocolate, etc.
- **Urine output** Ask whether the child has passed urine or had a wet nappy recently. Oliguria is one of the early signs of shock.
- **Cold hands and feet, mottled skin** As septicaemia advances, cold hands and feet and mottled skin are signs of circulatory compromise that parents notice.

(Also see Clinical Signs of Septicaemic Shock p49)

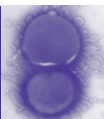
SYMPTOMS OF MENINGITIS

The main symptoms of meningitis are all due to the dysfunction of the central nervous system. Be aware that symptoms can vary according to the age of the child. Symptoms include:

- **Fever**
- **Headache**
- **Vomiting**
- **Drowsiness/confusion**
- **Fits**
- **Photophobia** (less common in young children)
- **Neck stiffness** (less common in young children)

(Also see Clinical Signs of Meningitis p49)

Young children may have fever and vomiting associated with irritability, drowsiness and confusion. **They may be very hard to assess and parent's**



Section 4 | Making the Diagnosis

anxieties about their state of responsiveness and alertness must always be taken seriously.²²

Older children are more likely to have fever, vomiting and complain of headache, stiff neck and photophobia.⁷

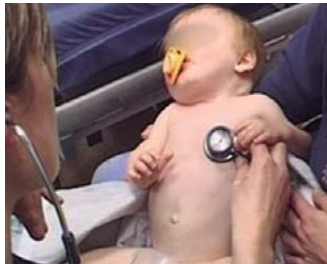Teenagers may present with symptoms related to a change in behaviour such as confusion or aggression. These may mimic the symptoms of alcohol or drug intoxication²³.

B. EXAMINING THE PATIENT

INITIAL ASSESSMENT OF ANY FEBRILE CHILD

For all febrile children the following should be undertaken:

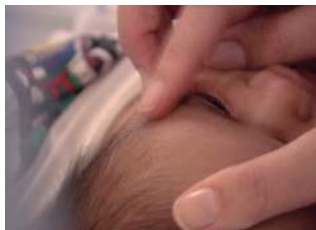- Fully undress and examine systematically. Make a thorough search for a focus of infection: think about the 'hidden sites' such as meninges, urinary tract and bloodstream (septicaemia). Mildly pink tympanic membranes or throat do not constitute a focus. It is best to start the examination whilst the child is not crying. It takes time to make a careful assessment.



This child is febrile and looks ill and pale.

Babies are the hardest to assess, as they are uncooperative when ill, and it is often difficult to pinpoint where the infection is coming from. When a baby is lethargic and quiet, but irritable when moved: this can be a sign of meningitis.

- If a rash is found, it is important to decide whether it is non-blanching.



A child with a non-blanching rash and fever, or history of fever, requires immediate action and a senior paediatrician should be informed.

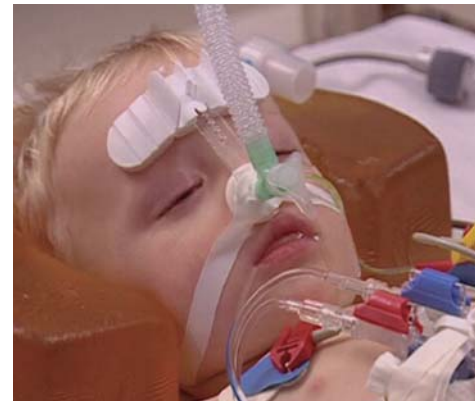Meningococcal disease is not the only cause of non-blanching rashes in children, but approximately one in ten children with meningococcal disease dies, and most fatal cases die within 24 hours of the onset of symptoms. The window of opportunity for delivering effective treatment is therefore brief, and the consequences of waiting to confirm the diagnosis before commencing treatment can be very grave.

All febrile children with haemorrhagic rashes must be taken very seriously.

Although many children with fever and petechiae will have viral illnesses^{17 28 29} there is no room for complacency when assessing these children. They must all have their vital signs measured, a decision made as to whether they have signs of meningitis or septicaemia and given intravenous antibiotics. A senior paediatrician should be informed immediately.

Haemorrhagic rashes

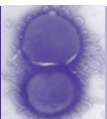
Petechiae <2mm diameter, purpura ≥2mm diameter. Purpura are highly predictive of meningococcal disease and should be treated as an emergency, with immediate antibiotics and admission. Petechiae alone are less predictive, but must be taken very seriously and especially in combination with other features of septicaemia should provoke urgent action. Some hospitals in the UK may have local protocols on action to take when a haemorrhagic rash is found, depending on whether the rash is petechial or purpuric, and there is work underway to consolidate this⁴⁸.



Children without a rash can still have meningococcal disease

Children without a rash or with a blanching rash can still have MD. The rash may appear later or not at all if the child has pure meningitis and occasionally with septicaemia.

- Thorough clinical assessment should ascertain whether there are physical signs of serious systemic illness.
- If initial assessment of airway, breathing and circulation reveals that you are dealing with a seriously ill child, ABC should be rectified in line with APLS guidelines³⁰ before proceeding with the detailed examination.



Section 4 | Making the Diagnosis

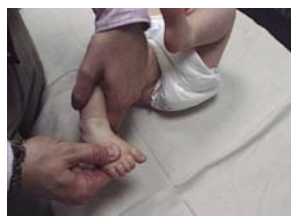The following clinical signs must be measured and recorded to complete a full assessment:

- Temperature
- Heart rate
- Respiratory rate
- Blood pressure
- Capillary refill time (CRT) or toe-core temperature gap

NORMAL VALUES OF VITAL SIGNS

Age	HR/min	RR/min	Systolic BP
<1	110-160	30-40	70-90
1-2	100-150	25-35	80-95
2-5	95-140	25-30	80-100
5-12	80-120	20-25	90-110
Over 12	60-100	15-20	100-120

From *Advanced Paediatric Life Support—the Practical Approach*.³⁰



Measuring capillary refill time

Standard technique for measurement of CRT is to press for 5 seconds on a fingertip or toe, or on the centre of the sternum, and count the seconds it takes for colour to return (shown here on dorsum of foot to facilitate capture on film).

- **Oxygen saturation measurement** (normal value is >95% in air)
- **Assessment of conscious level.** AVPU is a quick way to assess conscious level

Assess the best response patient can make:

- Alert? Remember, even an alert child may be very ill with septicaemia.
- Responds to **V**oice? Should be seen by doctor urgently
- Responds to **P**ain? Medical emergency
- Unresponsive? Medical emergency

■ Pupil size and reaction

- If rash present record whether it is blanching, extent of rash, speed of development and whether it is petechial or purpuric. See box on previous page, and The Rash on pages 51-56.

ASSESSMENT OF A FEBRILE CHILD WITH SUSPECTED MENINGOCOCCAL DISEASE

If MD is suspected, the purpose of the initial assessment should be to identify whether shock or raised intracranial pressure is present and the severity of the illness.

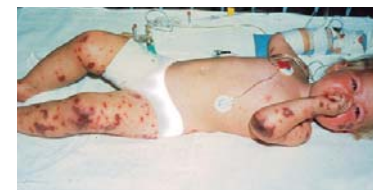CLINICAL SIGNS OF SEPTICAEMIC SHOCK

Septicaemia will lead to shock and multi-organ failure. Shock is a clinical diagnosis. The signs are a result of circulatory failure. The underlying pathophysiology of septicaemia and the capillary leak syndrome leading to these signs are briefly summarised in the Pathophysiology section.

A child in early shock may still be alert and have a normal blood pressure.

The early signs of shock include:

- **Tachycardia**
- **Cool peripheries** (CRT>4 seconds) or toe-core temperature gap of >3 degrees
- **Pallor, mottling**
- **Decreased urine output** (<1ml/kg/hr)
- **Tachypnoea** – secondary to acidosis and hypoxia

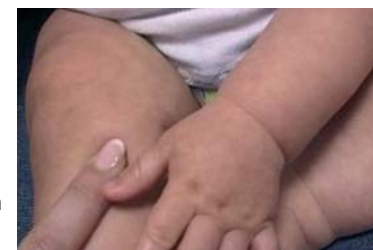

Child lucid despite advancing septicaemia

(In patients with meningococcal disease, signs of shock will usually co-exist with symptoms of septicaemia.)

As shock progresses further signs develop:

- **Metabolic acidosis with base deficit worse than -5**
- **Hypoxia:** PaO₂ <10kPa in air or saturation < 95% in air
- **Increasing tachypnoea, tachycardia and gallop rhythm**



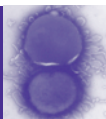
Mottled skin in a baby who also has prolonged CRT

Late signs of shock include:

- **Drowsiness or agitation**
- **Hypotension:** in children, blood pressure can be normal until shock is advanced

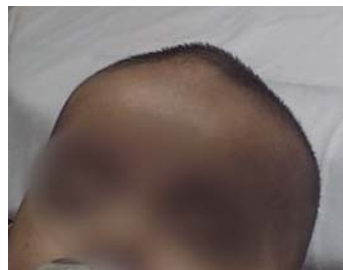CLINICAL SIGNS OF MENINGITIS

When examining a child for signs of meningitis it is crucial to remember that the younger a child the less likely it will be to have neck stiffness or photophobia (especially those <2 years of age). Be guided by the parents as to whether the child is drowsy or behaving inappropriately. Often parents are quick to recognise that the cry of a baby has changed or they are making poor eye contact.



Section 4 | Making the Diagnosis

- Babies with meningitis may have a **full or bulging fontanelle** due to raised intracranial pressure.
- They may feel stiff or have jerky movements or they may be very floppy. Fits are common.
- Drowsiness or decreased conscious level (or fluctuating level) is a very important sign in children of all ages.
- Teenagers with meningitis often present in an aggressive and combative manner rather than becoming drowsy. Drug and alcohol intoxication may be suspected²³.
- Rash: can be present, but more likely to be absent, atypical, scanty or petechial than in septicaemia.



Bulging fontanelle in a baby with meningitis. Not a common sign but significant when present.

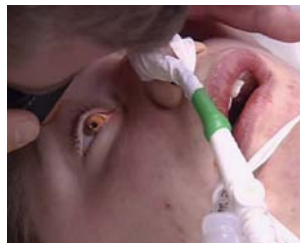(Also see Symptoms of Meningitis)

CLINICAL SIGNS OF RAISED INTRACRANIAL PRESSURE (RICP)

Children with meningitis are at risk of developing RICP (see Pathophysiology).

Signs of RICP are:

- Falling or depressed conscious level
- Abnormal posturing; decorticate or decerebrate
- Dilated pupils or unequal pupils
- Focal neurology
- Bradycardia and hypertension
- Abnormal breathing pattern
- Cushing's triad: slow pulse, raised blood pressure and abnormal breathing pattern – late sign of RICP
- Papilloedema is a late sign, its absence does not mean there cannot be any RICP



Looking for papilloedema

Note: Health care workers are encouraged to wear masks when carrying out procedures that may result in exposure to infectious respiratory droplets, for example during resuscitation⁴⁶

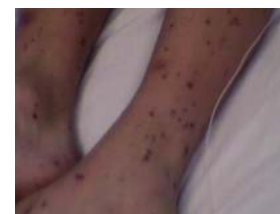Patients with RICP may have prolonged capillary refill time and a mild metabolic acidosis. If these signs are present in a patient with a normal heart rate or bradycardia, and a normal or high blood pressure, then they are not due to shock.

The diagnosis of raised intracranial pressure is a clinical one:

- Routine CT scanning is not indicated in patients with meningitis as CT scans are not sensitive in picking up signs of RICP^{31 32}. It is dangerous to put a child with fluctuating conscious level into the scanner without securing the airway first.
- Lumbar puncture is contraindicated in patients with signs of raised intracranial pressure as 'coning' can be precipitated^{33 34}.

THE RASH

Most patients with meningococcal septicaemia develop a rash^{7 24 25 26} – it is one of the clearest and most important signs to recognise. A rapidly evolving petechial or purpuric rash is a marker of very severe disease.

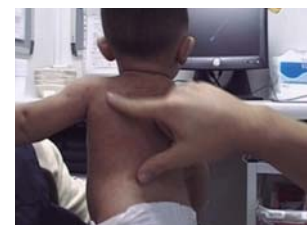

Non-blanching haemorrhagic rash

A non-blanching haemorrhagic rash is characteristic of meningococcal disease, and a rapidly evolving purpuric rash is a feature of severe disease, requiring urgent, aggressive treatment. But this rash is seldom an early sign, and the underlying disease may be advanced by the time a rash appears. In meningococcal disease, the rash may be absent, scanty, or it may be blanching in the early stages, especially in pure meningitis

Early stages

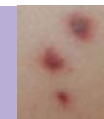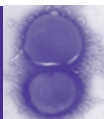
In the early stages the rash may be **blanching** and **macular** or **maculopapular**^{24 27} (sometimes confused with flea bites), but it nearly always develops into a non-blanching red, purple or brownish petechial rash or purpura.



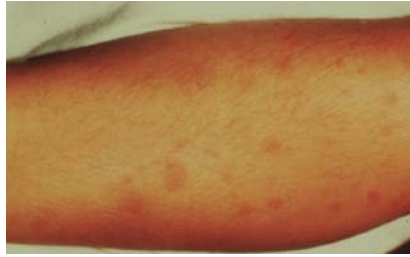A baby with a blanching rash

***Blanching rash:** All febrile children should be checked for a rash. If rash is present, check to see if it blanches on pressure. **A non-blanching rash in a febrile child requires immediate action.** However, the rash of meningococcal sepsis can start as a blanching rash so always check that the child does not have signs of shock or meningitis.*

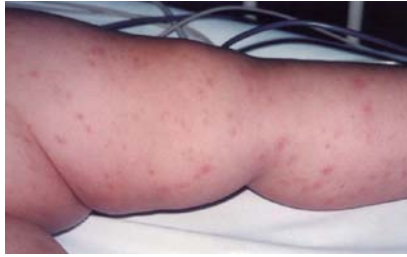Isolated pin-prick spots may appear where the rash is mainly **maculopapular**²⁴, so it is important to search the whole body for small petechiae, especially in a febrile child with no focal cause.



Section 4 | Making the Diagnosis

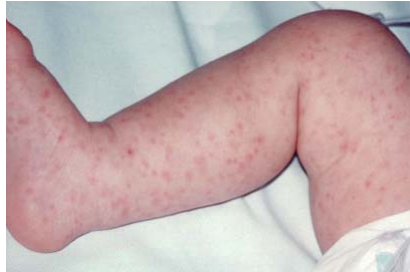

Macular rash

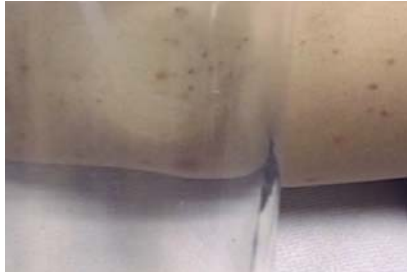

Maculopapular rash in meningococcal septicaemia

(Courtesy Dr A Riordan)



Maculopapular rash with scanty petechiae

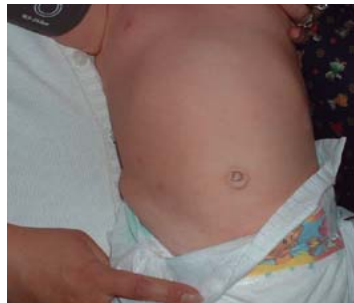

The haemorrhagic rash of meningococcal septicaemia does not fade under pressure. This is nicely shown by pressing the skin with a glass tumbler

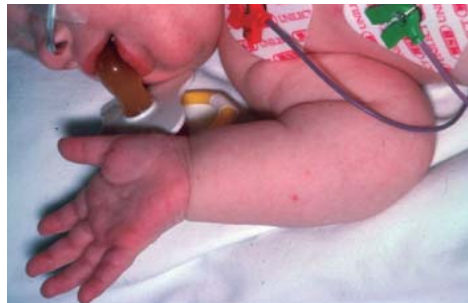(Courtesy Dr A Riordan)

Rash in meningitis

In meningitis the rash can be scanty, blanching (macular or maculopapular), atypical or even absent.



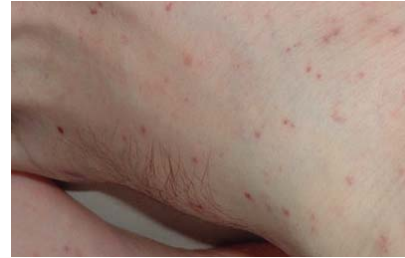Very scanty rash: just 3 petechiae on abdomen (2) and chest (1)*



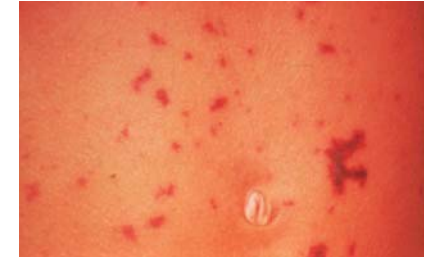A few petechiae on mottled skin

Spectrum of meningococcal rashes

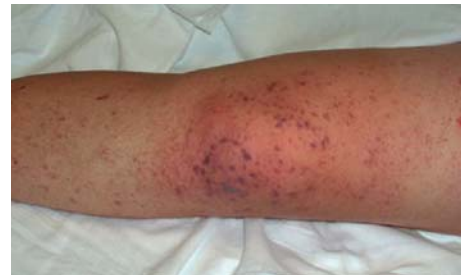Meningococcal rashes can be extremely diverse, and look different on different skin types. The rate of progression can also vary greatly.



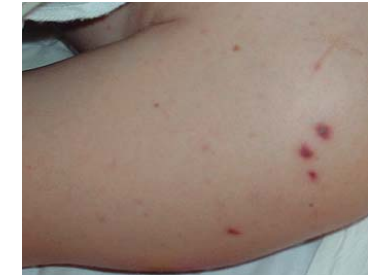Petechial rash*



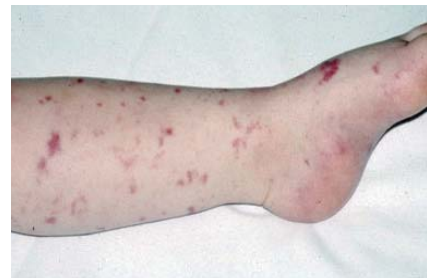Mixed petechial/purpuric rash



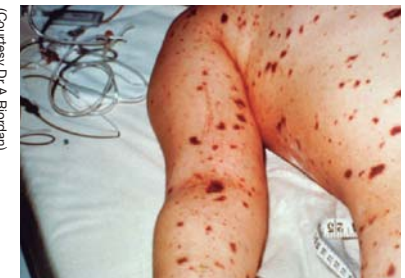Mixed petechial/purpuric rash* on freckled skin



Sparse purpuric rash*

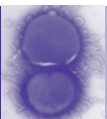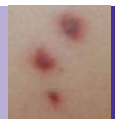


Full-blown purpuric rash of septicaemia

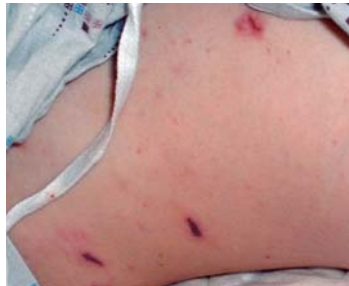

Widespread purpuric rash of septicaemia

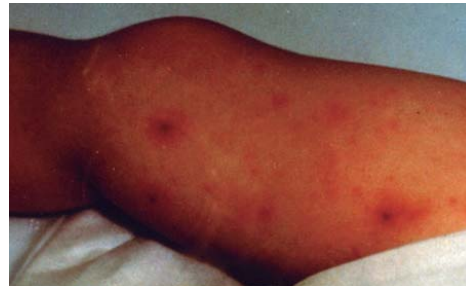(Courtesy Dr A Riordan)



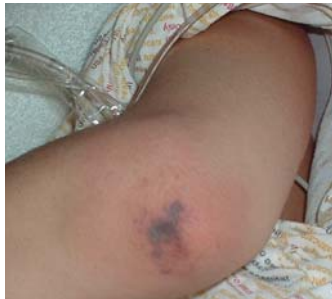Section 4 | Making the Diagnosis



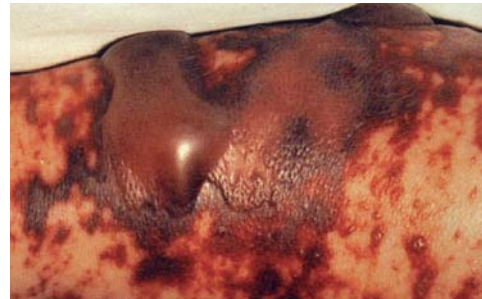Atypical purpuric marks*



Atypical purpuric spots can resemble insect bites *



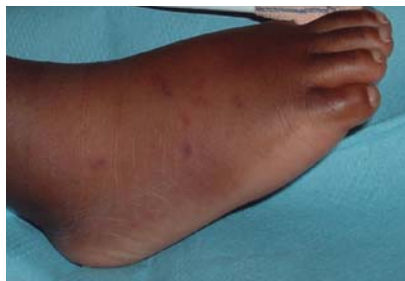Purple blotches may be larger, resembling bruises*



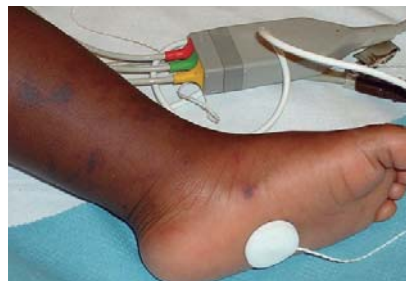Purpuric blotches of septicæmic rash can resemble blood blisters *

Spotting the rash on dark skin

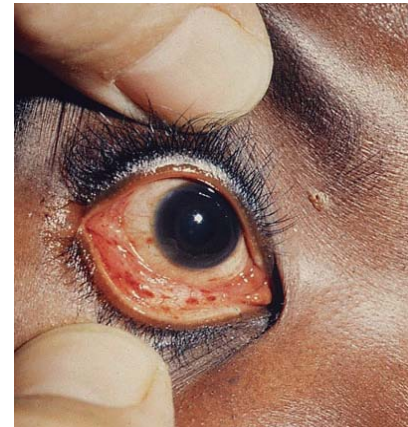The rash can be more difficult to see on dark skin, but may be visible in paler areas, especially the soles of the feet, palms of the hands, abdomen, or on the conjunctivæ or palate.



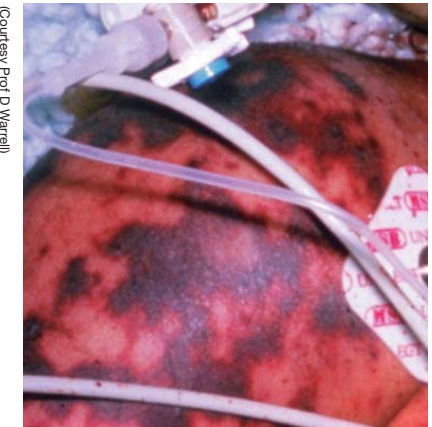Meningococcal rash on dark skin *



Purpuric rash on dark skin - easier to see on sole of foot*



Petechial rash on conjunctivæ

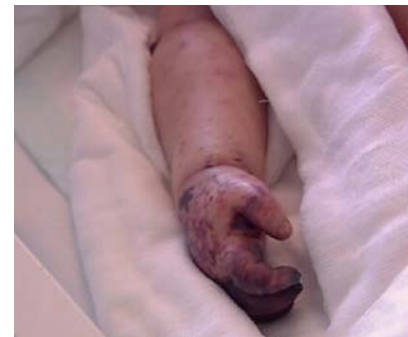

Widespread purpuric rash on dark skin^

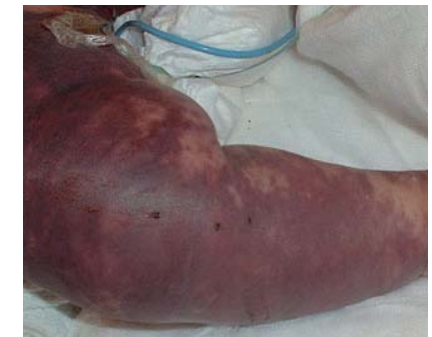Advanced rash

Purpuric areas that look like bruises can be confused with injury or abuse.

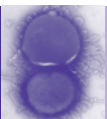
Extensive purpuric areas are usually called 'purpura fulminans'. The extremities are normally worst affected: often the feet and hands and sometimes the ears, nose or lip. In the photo on the left, it has mainly affected the child's hands but it can extend over a whole leg (or) arm, as in the photo on the right.



Purpura fulminans on the hand



Purpura fulminans over the whole leg



Section 4 | Making the Diagnosis

Development of meningococcal rashes

It is crucial to remember that the underlying meningitis or septicaemia may be very advanced by the time a rash appears. The rapidly evolving haemorrhagic 'text book' rash may be a very late sign, it may be too late to save the child's life by the time this rash is seen. It is very important to examine children for the signs of meningitis or septicaemia (and RICP or shock) and investigate and treat if necessary based on those findings.

Although some of the causes of petechial rashes are self-limiting conditions, many others, including MD are fulminant or life-threatening, and a non-blanching rash should therefore be treated as an emergency^{5,19}.

C. INVESTIGATION

INITIAL LABORATORY ASSESSMENT

The tests below should be done on all suspected cases of MD and children who are suspected of having an invasive bacterial infection:

- **Glucose**
- **Full blood count**
- **Electrolytes and urea**
- **Calcium and magnesium** (metabolic derangements are common in septicaemia and may contribute to myocardial dysfunction)
- **Phosphate**
- **Clotting studies**
- **Venous blood gas** to measure base excess
- **Blood culture**
- **Throat swab culture**
- **Meningococcal PCR** whole blood (EDTA specimen) to send to reference laboratory

Parameter	Normal range*
Hb	10.5 to 13.5 g/dL
WCC	5.0 to 15.0 (x10 ⁹)
Platelets	150 to 450 (x10 ⁹)
Base Excess†	0 to -3 mmol/L
pH	7.35 to 7.45
HCO ₃	22 to 26 mmol/L
PaO ₂	10 to 13.5kPa or 75 to 100mmHg
PaCO ₂	4.6 to 6kPa or 34.5 to 45 mmHg
Glucose	3.6-5.2 mmol/L
Urea	2.5 to 6.0 mmol/L
Creatinine	19 to 43 mmol/L
Na	133 to 146 mmol/L
K+	3.5 to 5.5mmol/L
Mg++	0.66 to 1.0 mmol/L
Total Calcium	2.17 to 2.44 mmol/L
PO ₄	1.60-2.90 mmol/L
INR	1
PT	9.9 to 12.5 seconds
APTT	26.0 to 38.0 seconds
TT	9.2 to 15.0 seconds
Fibrinogen	1.7 to 4.0 g/L

* Please note that normal ranges for many variables can differ among hospitals.

† Blood gas reports measurement of base excess (BE), which, when negative indicates that there is a base deficit (acidosis).

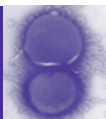
LUMBAR PUNCTURE

Lumbar puncture (LP) can be important for treatment if the clinical diagnosis is in doubt, particularly in children who are febrile without a focus. For children with obvious meningeal symptoms, microbiological confirmation is valuable for:

- duration of treatment
- decisions about prophylaxis and public health management
- follow up care of children who recover with neurological sequelae, and
- disease surveillance.

However, LP must not be performed when there are contraindications and should never delay treatment. With modern PCR techniques, CSF samples may still be positive after antibiotics have killed the organisms.

Check with a senior colleague if you are unsure.



Section 4 | Making the Diagnosis

THE APLS CONTRAINDICATIONS TO LUMBAR PUNCTURE³⁰

- Prolonged or focal seizure
- Focal neurological signs (including ocular palsies)
- Widespread purpuric rash in ill child
- Glasgow coma score <13
- Pupillary dilatation
- Impaired oculocephalic reflexes
- Abnormal posture
- RICP: inappropriately low pulse, elevated blood pressure and irregular respirations (indicating impending brain herniation).
- Coagulopathy
- Papilloedema
- Hypertension

Lumbar puncture should also be avoided where there is any cardiovascular or respiratory compromise or if there is local infection at the site of LP.

D. GLASGOW MENINGOCOCCAL SEPTICAEMIA PROGNOSTIC SCORE

The Glasgow Meningococcal Septicaemia Prognostic Score (GMSPS) is composed of 7 parts, 6 clinical and 1 laboratory value. It is described below.

Observation	Score
BP <75 mmHg age <4 <85 mmHg age ≥4	3
Skin / rectal temp difference >3	3
Modified coma score <8 or deterioration of 3 points or more in 1hr	3
Deterioration in 1 hour before scoring	2
Absence of meningism	2
Extending purpuric rash or widespread purpura	1
Base deficit > 8	1
Maximum total score	15

The GMSPS was first described in 1987 by Sinclair³⁵. It was devised to assign patients presenting with meningococcal disease to a prognostic category. It is a clinical score that has been validated for use in hospitals when patients first present³⁶. The score was devised to try and identify, at the point of admission to hospital, those patients most likely to have severe meningococcal disease and die. Originally a threshold score above or equal to 8 on admission was associated with a poor outcome. As treatments for meningococcal disease have improved the threshold score has increased.

Use of the GMSPS

It is useful to score all patients with presumed meningococcal disease when they are admitted to hospital as the score does focus on the clinical features of septicaemia. However, all children with presumed meningococcal disease should have the thorough clinical and laboratory assessment described in this booklet.

If a child has a low score (<8) on admission to hospital, do not assume that this child is not at risk of severe disease. It could be that you are assessing the child early in its disease course. Continue to manage the child according to the algorithm Early Management of Meningococcal Disease in Children, reproduced in this booklet.

It is important that regular repeated thorough clinical assessment is continued for the first 24-48 hours of the child's admission – repeated scoring using GMSPS is a useful way of categorising changes in severity of illness.

E. PITFALLS IN DIAGNOSIS

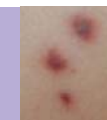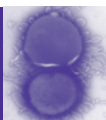
Every year children are sent home from hospital with undiagnosed meningococcal disease. This leads to wasted hours in which the disease progresses and children may die unnecessarily. Simple changes to clinical practice may help prevent this. Common pitfalls in practice are explained in this section.

Contacts of cases of meningococcal disease



The risk of meningococcal disease is elevated for school contacts of cases

People who have been in contact with cases of meningococcal disease are at increased risk of invasive disease. After a single case, close household contacts – usually family – are at the greatest risk, but there is an increased risk for school and nursery contacts as well³⁷.



Section 4 | Making the Diagnosis

Prophylactic antibiotics, usually rifampicin or ciprofloxacin, are given to reduce the risk of meningococcal disease by eradicating carriage in the group of close contacts of a case who are at highest risk. They do not prevent invasive disease developing if the bacteria have already invaded the bloodstream.

Case History: Contacts of Cases

12 year old boy presented with a short history of fever, feeling dizzy and nauseated. A member of his class was then on intensive care with meningitis. His mother was concerned that he might have the same illness.

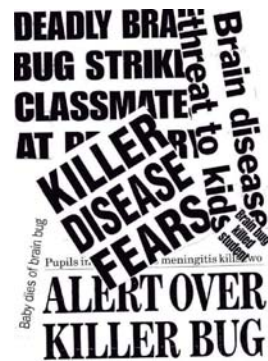On examination he was febrile, temp 38.5, alert and orientated.

He was assessed by a doctor who found that he was alert, with no neck stiffness or photophobia. He did not have a rash and his chest was clear. The doctor diagnosed a viral illness and sent him home.

He returned 12 hours later with fulminant septicaemia and died.

Guidelines for the public health management of meningococcal disease are based on the statistical probability of further cases occurring and the risk/benefit balance of control measures that can be taken³⁸. Wider public health action only comes into play after two or more linked cases. Although the great majority of cases of meningococcal disease are sporadic and do not result in further linked cases, clusters of cases do occur. When assessing a child whose classmate has meningococcal disease, consider that this could be the second case that makes the cluster.

Diagnosing meningitis

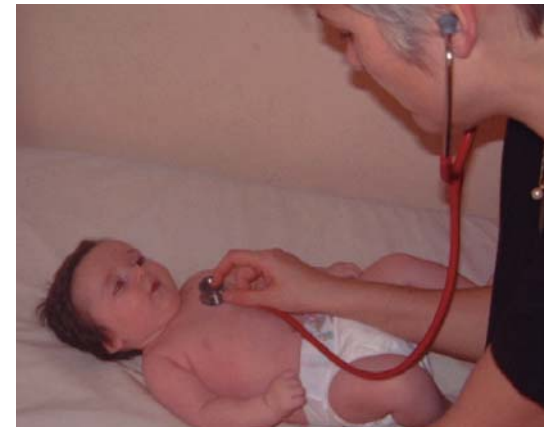

"Deadly brain bug" – common perception of meningococcal disease

The media portray meningococcal disease as meningitis even when the subject is a case of meningococcal septicaemia. When parents bring their child to you worried that they may have meningitis they actually mean that they are worried their child has that illness they read about in the paper characterised by fever and a rash.

Parents are usually not aware that there is a difference between meningitis and septicaemia and it is up to doctors to ask about the symptoms of sepsis and ensure that their clinical examination includes looking for shock.

Making a provisional diagnosis



Mistakes are made when doctors remain fixed with their initial diagnosis and do not think again as the case progresses

A diagnosis based only on symptoms should be viewed as changeable until you have confirmation from investigations.

When giving a child a presumptive diagnosis like 'febrile convulsion' or 'viral illness' remember it is just that – your best guess.

Case History: Making a Provisional Diagnosis

2 year old admitted with a history of fever, cough, fast breathing and fast pulse noted by the mother.

The child had experienced a 10 minute generalised convulsion at home.

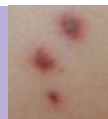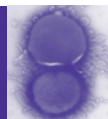
On admission the child had a fever of 39.3, Pulse 220 BPM, RR 35/min, saturations 99 and no rash noted.

A diagnosis of febrile convulsion was made and the child was admitted to the ward.

1 hour after admission the pulse was fast at 186, BP 95/50 and respiratory rate 50. No investigations were sent.

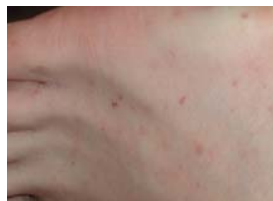2 hours after admission the child had a second fit for a few minutes. The medical staff decided that this was just a second febrile convulsion and did not change management or investigate. The persistent tachycardia and tachypnoea were not taken into consideration.

During the next 5 hours on the ward there were no recorded vital signs at all. Then the child was noted to have extending purpura and to be shocked. Full resuscitation was started but it was too late and the child died.



Section 4 | Making the Diagnosis

How much rash do you need to diagnose meningococcal disease?



A few petechiae

Especially in the early stages, or when meningitis predominates, rash may be scanty, blanching or even absent.

Remember that the process of meningitis or septicaemia can be quite advanced before the rash starts to appear, so if you suspect that a child may have meningococcal disease then do not wait for more rash to develop, treat the child immediately.

Case History: Amount of Rash

2 year old boy seen by the GP: acutely unwell with high temp, vomiting, lethargy, unable to keep fluids down. Extra concern - close contact has been diagnosed as having meningococcal meningitis

GP examination: fever 38.6, pale, no rash, tachycardic but not shocked, irritable on handling.

Seen in hospital: Pale and quiet Temp 39.6, P 155, RR 58, No rash, thirsty

Given paracetamol, vomited immediately

SHO examination: Very lethargic, sleepy but rousable, pale

RR 60, P140, No neck stiffness, 2 petechiae in nappy area

Diagnosis ? viral illness

Reviewed by registrar: diagnosis - this was likely to be a viral illness and to admit for observations, to have antibiotics if more rash appeared.

12 hours later – consultant ward round – looking worse with more rash.

Investigations initiated.

Hb 10, WCC 22.5, PI 244

pH 7.29, pCO2 4.39, pO2 4.6, BE -10

INR 2.0, APTR 1.3

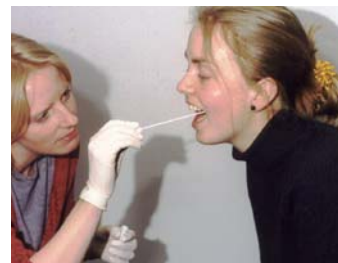Child deteriorated quickly at this point and died.

Other rashes

If you diagnose a child as having another illness characterised by a rash, make sure that your diagnosis is likely or even possible.

You may be sure of your diagnosis, but if you decide the child is well enough to be sent home, remember to advise parents to return if their child becomes more unwell, even if this is only shortly after being seen.

Teenagers



Approximately 25% of teenagers carry meningococci in the nasopharynx

Teenagers are a vulnerable group. There is a secondary peak in incidence of meningococcal disease amongst young adults aged 15-20 years, with an increased risk of mortality³⁹. As shown in this booklet, in the section Development of Symptoms in Meningococcal Disease, signs and symptoms develop later in teenagers than in younger children. Teenagers present to GPs and to hospital later than younger children do, and on average the disease is further advanced in teenagers by the time they get to hospital.

Case History: Teenagers

14 year old boy referred by the GP with diarrhoea and vomiting, abdominal pain and shivering. The GP thought the child was grey and unwell.

He walked into ED - no rash, alert and orientated. HR 160, RR20, Temp 39, BP80/40, saturations 96% in air.

After 30 minutes he developed rapidly spreading purpura.

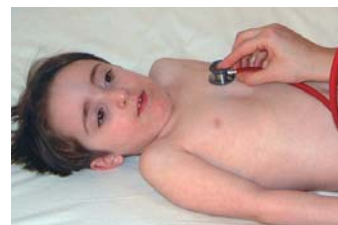Hb 13.7, WCC 1.4, platelets 9.

Na 134, K 3.2, Urea 6.2, creat 163

PH 7.1, pCO2 4.9, pO2 4.1, BE -13.8

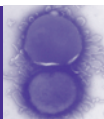
He was resuscitated aggressively but died.

Does your diagnosis make sense?



Assessing febrile children and trying to decide what is wrong with them is one of the most difficult tasks in paediatrics

It takes time to take a good history and examine a child properly. Before you discharge the patient from your care make sure that what you have done makes sense and that you can explain your actions and decisions to anyone who may ask.

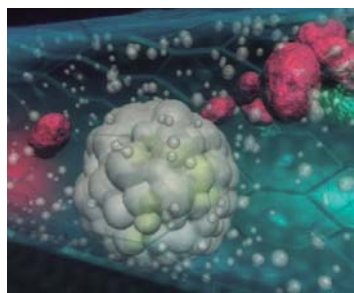
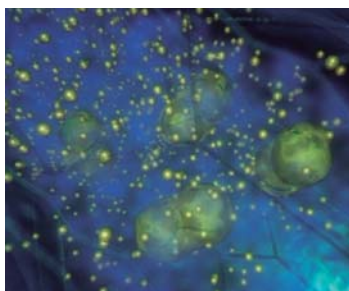
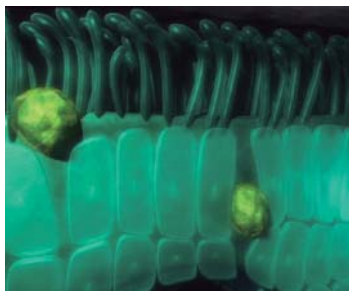


UNDERSTANDING THE PATHOPHYSIOLOGY OF MENINGOCOCCAL INFECTION AND THE PRINCIPLES OF MANAGEMENT

The principles of management of meningitis and septicaemia are best understood by having a basic knowledge of their pathophysiology⁴⁰. The following summary is covered in more detail in the articles listed in the references section.

Meningococci commonly colonise the human nasopharynx. About one in ten of us typically carries them in the nose and throat, and usually this is harmless. However, in some people, the bacteria are able to penetrate the defensive mucosal lining of the nose and throat to enter the bloodstream.

Once in the bloodstream, meningococci multiply rapidly, doubling their numbers every 30 minutes. In some individuals, they cross the blood-brain barrier, producing inflammation and swelling in the meninges and the brain tissue itself. This causes raised intracranial pressure, which can lead to neurological damage and death. Meningococci in the bloodstream cause septicaemia. As they multiply, they shed blebs from their outer coat. These contain endotoxin. Endotoxin is the prime initiator of gram-negative bacterial septic shock. It is a lipopolysaccharide component of the bacterial outer membrane. Levels of circulating endotoxin correlate with disease severity.



As the meningococci release endotoxin, white cells try to engulf them to overcome the infection, releasing a flood of pro-inflammatory cytokines, including IL-1, IL-6, and TNF. This damages the endothelial lining of the blood vessels. Endothelial damage activates the coagulation cascade and anti-clotting pathways are down-regulated, leading to a pro-coagulant state. Platelets rush to the site of damage to repair the endothelium. Clots start to form. Blood and other fluid haemorrhages out of the damaged vessels into

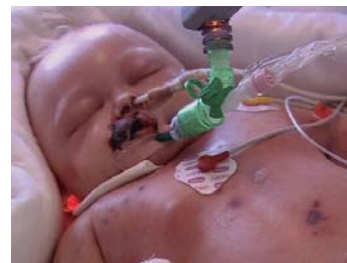the surrounding tissues. This occurs in all small vessels in the body but is most obvious in skin, hence the hallmark non-blanching rash. Widespread clotting and haemorrhaging in small vessels in fingers, toes and sometimes entire limbs can lead to necrosis and eventual amputation. The same processes in kidney, lung and other organs can cause multiple organ failure and death.

CLINICAL PATHOPHYSIOLOGY OF SEPTICAEMIA

The main processes involved in the pathophysiology of septicaemia are **increased vascular permeability**, **myocardial dysfunction** and **disseminated intravascular coagulation**.

INCREASED VASCULAR PERMEABILITY

When meningococci invade the bloodstream, endotoxin is released from the bacteria. This triggers an inflammatory response, with release of inflammatory mediators, which is directed against the endothelial surface lining the blood vessels. One of the main functions of the endothelium is regulation of vascular permeability, and disturbance of this function causes the endothelial lining to become 'leaky', allowing increased passage of protein and water from the intravascular to extra-vascular compartments, causing a 'capillary leak syndrome'. The patient becomes hypovolaemic due to reduction in circulating volume, thus reducing cardiac output.



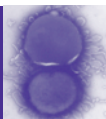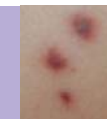
Severe meningococcal septicaemia: this baby's body is bloated with fluid that has leaked from damaged blood vessels

Due to 'capillary leak syndrome', plasma water has leaked from damaged blood vessels into the tissues, and the baby is in shock. In severe cases, resuscitation may require giving twice a child's blood volume. Some of the fluid given to restore the circulating volume leaks into the tissues. The increased vascular permeability may continue for hours or days. Once the patient starts to recover the fluid is reabsorbed into the circulation and got rid of through the kidneys. This baby is ventilated to minimise the work of the heart and prevent her developing pulmonary oedema.

In compensation for reduced circulating volume, heart rate and contractility increase, and perfusion to skin and the splanchnic circulation is reduced. Therefore signs of hypovolaemia in sepsis include:

- **Tachycardia**
- **Tachypnoea**
- **Cool peripheries**
- **Reduced urine output**
- **Irritability or lethargy.**

Note that in the early phases of septic shock, blood pressure is maintained by these compensatory mechanisms. This means that early in shock, children are alert as blood flow to the brain is being maintained at the cost of the other organs.



MYOCARDIAL DYSFUNCTION

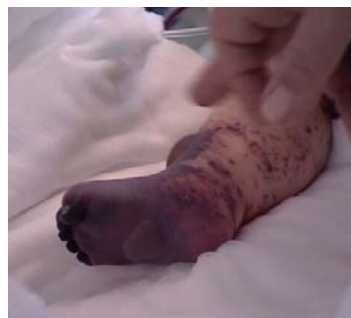Endotoxin and inflammatory mediators (such as IL6)⁴¹, together with other poorly-defined 'myocardial depressant factors' reduce myocardial contractility. In addition, a myocardial cytotoxic process causes myocardial cell necrosis.

Hypovolaemia and myocardial dysfunction contribute to progression of shock. In addition, nitric oxide and other vasoactive mediators cause a relative 'vasoparesis' and relative inotrope unresponsiveness.

Progression of shock leads to tissue hypoxia and capillary leak leads to pulmonary oedema resulting in tachypnoea and hypoxia.

Eventually, compensatory mechanisms fail and blood pressure falls. This is a late and serious sign in septic shock in children.

DISSEMINATED INTRAVASCULAR COAGULATION



Purpura fulminans, affecting this baby's foot

Purpura fulminans, due to damaged vessels and disseminated intravascular coagulation. There is thrombosis in the small vessels in the skin. Some of the skin has blistered like dead skin after a burn. Skin grafts will be needed to cover these black areas.

The deeper tissue is also affected: the ends of the toes are black and shrivelled. The tissues there are dead and will most likely auto-amputate. It is often not possible to know the full extent of the tissue damage at this early stage. As time progresses clear marks of demarcation between viable and dead tissue become clear.

Endotoxin and the inflammatory response leads to activation of the coagulation cascade and down-regulation of anticoagulant and fibrinolytic pathways, leading to a procoagulant state. Clotting times are prolonged and thrombocytopenia occurs.

Microvascular thrombosis contributes to multiple organ failure and purpura fulminans.

Amputations:

When purpura fulminans occurs, some tissues are irreversibly destroyed due to thrombosis within the microvasculature, combined with vasoconstriction and ischaemia in peripheries. Haemorrhagic necrosis in skin and clotting in small vessels can lead to loss of skin, digits or limbs.

SPECIFIC ORGAN DYSFUNCTION IN SHOCK

Respiratory failure

(arterial PO₂ <10kPa in air or PCO₂ >6)

Common in shock. Capillary leak into lung parenchyma → acute pulmonary oedema. **Clinically:** tachypnoea, chest wall retraction, hypoxia.

Neurological dysfunction

In septicaemia, patients may be alert until late in the illness. Falling conscious level results from impaired cerebral blood flow and disturbed brain metabolism due to hypotension, hypoxia and acidosis.

Metabolic derangement

Septicaemia causes profound acidosis and derangements in metabolism, which may affect myocardial function and need correcting. Hypoglycaemia is common. Hypokalaemia, hypocalcaemia, hypomagnesaemia and hypophosphataemia all occur.

Myocardial failure

Depressed myocardial function is multifactorial, including endotoxin, cytokines, multiple metabolic derangements, hypoxia, and hypovolaemia.

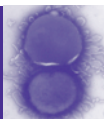
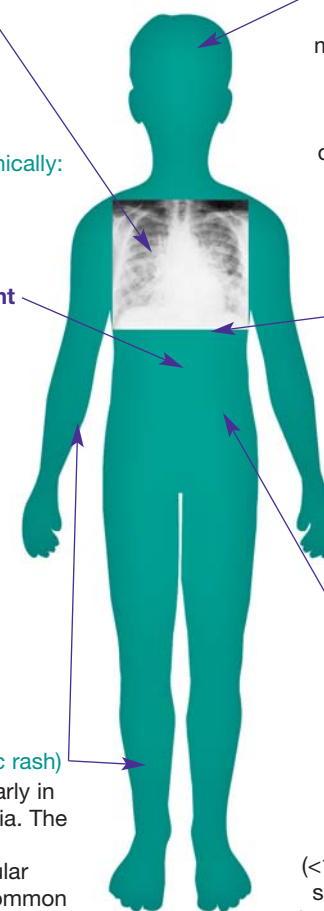
Clinically: tachycardia, gallop rhythm, cool peripheries and eventually hypotension.

Coagulopathy (purpuric rash)

Coagulopathy occurs early in patients with septicaemia. The laboratory findings of disseminated intravascular coagulation (DIC) are common in such patients. Coagulopathy is generally associated with the presence of a purpuric rash, but significant coagulopathy may infrequently occur in the absence of purpura.

Renal failure

Little or no urine output (<1ml/kg/hour) is a very early sign in septic shock, initially due to hypovolaemia. If shock persists then renal failure may occur. Serum creatinine ≥2 times upper limit of normal for age or 2-fold increase in baseline creatinine indicates renal dysfunction.



CLINICAL PATHOPHYSIOLOGY OF MENINGITIS

Meningococcal meningitis generally has a better prognosis than septicaemia. Meningococci reach the brain from the bloodstream, implying that the patient's immune response has prevented bacterial proliferation in the blood and not suffered overwhelming sepsis. This is because organisms are handled differently in these patients, which is probably due to differences in their inflammatory response to infection as well as different bacterial characteristics.

Deaths do occur, however due to the severity of the inflammatory process within the brain.

Once bacteria penetrate the blood-brain barrier, endotoxin and inflammatory mediators initiate a CSF inflammatory response, causing leakage of protein and fluid out of the cerebral vasculature. In addition, the processes delineated in septicaemia occur in brain blood vessels, causing cerebral oedema and cerebral vascular thrombosis. As a consequence there is an increase in brain water content and an increase in intracranial pressure. Both the increased pressure and thrombosis may lead to a reduction in cerebral perfusion, and consequently cerebral infarction and sometimes brain death.

MANAGEMENT OF SEPTICAEMIA AND MENINGITIS

The aim of this section is to outline the principles of management of septicaemia and meningitis which are based on understanding the pathophysiology. A fuller explanation of the management of meningococcal disease can be found in *Archives of Disease in Childhood*⁴⁵. The protocol from this article has been published as '**Early Management of Meningococcal Disease in Children**' and at the back of this handbook. It is also available as a leaflet or poster from Meningitis Research Foundation, and in interactive electronic format in the e-learning tool that is companion to this handbook.

Antibiotics - cefotaxime or ceftriaxone

- All children with fever and a haemorrhagic rash
- Children with shock with or without a rash
- Children with clinical evidence of meningitis. If lumbar puncture is contraindicated (see page 51), treat immediately with antibiotics and lumbar puncture when safe (but a full set of bloods as well as throat swabs for culture should be taken if not already done). Consider adjunctive **dexamethasone** before, with or within 4 hours of the first dose of antibiotics, if there are no signs of septic shock⁴²

Door to needle time⁴³

Once the decision to give antibiotics has been taken, ensure they are written up and given within 30 minutes. Unacceptable delays in giving antibiotics can occur when responsibility for this is delegated without personal follow up.

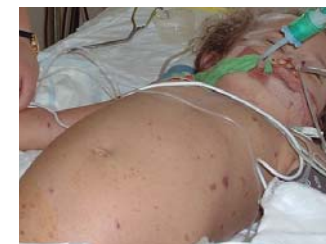PRINCIPLES OF MANAGEMENT OF SEPTICAEMIA WITH SHOCK

This section provides a narrative description of the management plan outlined in the protocol Early Management of Meningococcal Disease in Children.

Children with evidence of shock need immediate resuscitation:

- Assess airway for patency
- Give oxygen to all patients even if oxygen saturations are normal in order to optimise tissue oxygenation
- Secure good venous access. The goal of circulatory support in shock is the maintenance of tissue perfusion and oxygenation. Remember in shocked children the intra-osseous route may be the most effective way of giving large volume replacement.

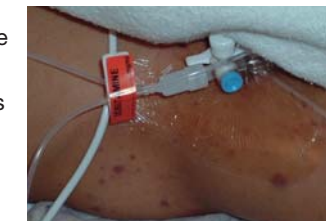- Rapid fluid resuscitation should be initiated. Boluses of 20ml/kg of colloid (preferably 4.5% albumin⁴⁴) or crystalloid solutions should be given rapidly (over 5-10 minutes) whilst monitoring the clinical response (HR, RR, BP, CRT, O₂ sats, urine output, conscious level). If the clinical response is short-lived or absent, and shock does not improve or progresses, large volumes may be required (over 60ml/kg in the first hour). There is evidence from adults that early goal-directed resuscitation of patients with septic shock is associated with an improvement in outcome⁴⁵.



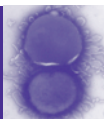
Bloated appearance due to capillary leak syndrome. Fluids given during volume resuscitation contribute to this at first.

- Hypoglycaemia (<3.3 mmol/l) is common and should be corrected: 5ml/kg 10% dextrose bolus i.v., then check glucose hourly and correct if necessary.
- If signs of shock persist after 40-60 ml/kg of fluid resuscitation, there is significant risk of pulmonary oedema, so elective tracheal intubation and mechanical ventilation should be initiated even if there are no signs of respiratory failure⁹. This will optimise oxygenation, reduce the work of breathing, and improve cardiac function.

- Advice to guide further management should be sought early.
- Invasive monitoring and central venous access will be required to guide fluid therapy and optimise support.
- Inotropic support may be required to optimise tissue perfusion and improve myocardial function.



Dobutamine can be infused centrally or peripherally



- Metabolic acidosis is common and impairs myocardial contractility. If $\text{pH} < 7.2$ due to base deficit, give half correction NaHCO_3 iv.
 - Volume (ml) to give = $(0.3 \times \text{weight in kg} \times \text{base deficit } \pm 2)$ of 8.4% NaHCO_3 over 20 mins.
 - In neonates, volume (ml) to give = $(0.3 \times \text{weight in kg} \times \text{base deficit})$ of 4.2% NaHCO_3 .
- Metabolic derangements of calcium, magnesium and potassium are common, and need frequent checking and correction.
- In cases of severe bleeding or profound clotting disorder, consider correction of coagulopathy with fresh frozen plasma, platelets and, if fibrinogen is low, cryoprecipitate. Correction of thrombocytopenia is not generally required, but if uncontrolled haemorrhage from venepuncture sites or mucous membranes occurs despite replacement of clotting factors, platelet transfusion may be required if platelets are below $50,000/\text{mm}^3$.

Remember – Call for senior help early. Sick septic children need experienced doctors. This is not the time to ‘have a go!’

PRINCIPLES OF MANAGEMENT OF MENINGITIS WITH RAISED INTRACRANIAL PRESSURE

See protocol Early Management of Meningococcal Disease in Children.

The main objective in managing patients with RICP is to maintain oxygen and nutrient delivery to the brain. **Call for senior help and Paediatric Intensive Care immediately if there are signs of RICP.**

- Patients with $\text{GCS} < 8$ or drop of 3 points in last hour, or fluctuating level of consciousness should have their airway secured by tracheal intubation and mechanical ventilation.
- Optimise ventilation to ensure normocapnia and avoid hypoxia. Cautious fluid resuscitation. Maintenance of circulating volume and adequate blood pressure is the goal. Overaggressive fluid resuscitation will exacerbate cerebral oedema. Only patients with shock require aggressive fluid resuscitation to ensure cerebral perfusion. Patients **without** shock require close monitoring and judicious fluid replacement depending on heart rate, blood pressure, urine output and metabolic acidosis.

Do not rely on capillary refill time to guide fluid management as this may be falsely prolonged in patients with RICP. Rely instead on the other markers of organ perfusion and circulatory status as described.

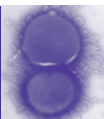
Consider the use of mannitol or hypertonic saline for acute changes in RICP as suggested by pupillary changes or sudden onset hypertension and bradycardia.

Nurse patient in head-up position, 20-30 degrees from horizontal. Avoid inserting

central venous lines into the internal jugular vein as this impedes venous drainage of the head and the insertion of the line may exacerbate the raised intracranial pressure.

PUBLIC HEALTH

- Doctor immediately notifies any suspected case of meningitis or meningococcal septicaemia by phone to the Consultant in Communicable Disease Control (CCDC), Consultant in Public Health Medicine (in Scotland) or on-call Public Health Specialist. This is the legal duty of the doctor who makes or suspects the diagnosis – usually the hospital doctor notifies even if the case was referred by a GP.
- After a single confirmed or probable (i.e. where MD is the most likely clinical diagnosis) case of meningococcal disease, only close contacts living in the same household as the case in the 7 days before disease onset, or kissing contacts need antibiotic prophylaxis³⁸.
- Healthcare staff only require prophylaxis if their mouth or nose has been splattered (clearly felt) with large particle droplets/secretions from the respiratory tract of a patient with confirmed or probable meningococcal disease, or if conjunctivitis develops within 10 days of exposure⁴⁶. This is unlikely to occur except when using suction during airway management, inserting an oro/nasopharyngeal airway, intubating, or if the patient coughs in your face.
- Public Health, usually the CCDC/CPHM arranges for prophylactic antibiotics to be prescribed to contacts as necessary. Rifampicin, ciprofloxacin (not in children under 2 or in pregnancy), and ceftriaxone (by injection) are all recommended for use in preventing secondary cases of meningococcal disease, but only rifampicin is licensed for this purpose. Rifampicin interferes with the oral contraceptive pill and stains body fluids red, including urine and saliva, and permanently stains soft contact lenses. Some individuals may experience rash or stomach upset.
- Antibiotic prophylaxis should eliminate carriage, but if the contact is already incubating the bacteria, he or she can still get the disease. Close contacts of a case need to understand that they are at increased risk of meningitis and septicaemia, and should be alerted to the symptoms, and given a leaflet on meningitis and septicaemia.
- The CCDC/CPHM will:
 - arrange for the next of kin to be interviewed to establish other close contacts and will arrange prophylaxis for them, and for later immunisation of all close contacts if indicated
 - ensure information is disseminated to appropriate local schools, work places and general practitioners
 - be responsible for early detection of clusters and outbreaks of disease.



Section 6 | Update on development of symptoms

The study which provided the clinical cases for this learning tool also collected data on the pre-admission symptoms of 448 children aged less than 17 years. Parents were asked to report the time the illness first started, the initial symptoms and all subsequent symptoms until hospital admission.

There has been very little information in the recent literature on this subject to guide doctors – published information about the development of symptoms generally relies on data collected from hospital patients. The results of this study provide the first description of the time course of the clinical features of meningococcal disease in children and adolescents prior to hospital admission.

Recognition of meningococcal disease can be difficult especially for doctors unfamiliar with the infection. Doctors may rely on the text book image of advanced meningococcal disease or look for symptoms more often reported in adults like neck stiffness and photophobia. It also does not help that doctors, parents and the media call this disease meningitis and so the importance of septicaemia is ignored or forgotten.

The full paper describing the pre-admission symptoms of the patients can be read in full in the Lancet⁷. A summary of the important findings is shown below.

CLINICAL FEATURES OF DISEASE

Table 1 (opposite) shows all the symptoms reported by parents and the median time it took for those symptoms to appear from the start of this illness. The children are grouped into 4 age bands as children within each age band have similar case fatality rates. The red lines in each column show the median time it took parents to take their child to a GP. From the figure it can be seen that it takes longer for older children to be taken to the doctor. This could be because their symptoms take longer to manifest or that their parents are less worried about them and respond less quickly.

EARLIEST SYMPTOMS

The earliest features were common to many self-limiting viral illnesses. Fever was the first symptom to be noticed in children aged under 5 years, headache in the older children and adolescents. Virtually all children (95%) developed fever at some point and most young children were miserable and irritable. Anorexia, nausea and vomiting were relatively early features at all ages, with many children also exhibiting upper respiratory symptoms (sore throat and coryza). This non-specific phase lasted for about 4 hours in younger children but as long as 8 hours in adolescents.

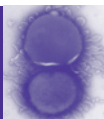
SEPSIS SYMPTOMS

The next symptoms to develop in all age groups were signs of sepsis and circulatory shut-down – limb pain, abnormal colour, cold extremities and, in older

Table 1: Median times of onset of clinical features of meningococcal disease prior to hospital admission.

Hours from onset	Age < 1 year		Age 1 - 4 years		Age 5 - 14 years		Age 15 - 16 years																									
	Median (IQR)*		Median (IQR)		Median (IQR)		Median (IQR)																									
0 - 4	Fever	0 (0, 6)	Fever	0 (0, 3)	Headache	0 (0, 12)	Headache	0 (0, 2)																								
	Miserable/irritable	0 (0, 7)	Miserable/irritable	2 (0, 10)					Sore throat/coryza	0 (0, 9)																						
	Poor feeding	1 (0, 9)																														
	Nausea/vomiting	1 (0, 11)																														
	Coryza	2 (0, 13)																														
	Drowsy	4 (0, 14)																														
5 - 8	Diarrhoea	5 (0, 9)			Leg pain	6 (0, 13)	Abnormal colour	5 (0, 29)			General aches	6 (0, 20)																				
	Abnormal colour	5 (0, 18)																														
	Breathing difficulty	5 (0, 19)																														
	Leg pain	7 (0, 15)																														
	Floppy tone	8 (1, 19)																														
	Rash	8 (4, 18)																														
9 - 12	Cold extremities General aches	9 (1, 20) 9 (4, 22)	Abnormal colour General aches Rash General aches Seizure Diarrhoea	9 (3, 18) 9 (4, 18) 9 (6, 18) 9 (4, 18) 9 (1, 18) 10 (6, 14)	Drowsy	9 (1, 21)	Decreased appetite	9 (3, 21)																								
									Cold extremities Confusion/delirium Neck stiffness Photophobia	11 (2, 17) 11 (5, 17) 11 (8, 17) 12 (6, 27)	Miserable/irritable Confusion/delirium	12 (2, 22) 12 (8, 24)	Nausea/vomiting	10 (3, 19)																		
															Photophobia Unconscious Bulging fontanelle Neck stiffness Seizure	13 (5, 17) 15 (6, 17) 15 (3, 20) 15 (2, 27) 16 (14, 31)	Floppy	13 (8, 20)	Cold extremities Rash Neck stiffness	14 (6, 27) 15 (13, 17) 16 (8, 26) 16 (6, 30) 16 (6, 32)												
																					Thirst	17 (7, 27)	Photophobia	17 (5, 39)	Photophobia Abnormal colour Rash	17 (5, 29) 18 (4, 29) 19 (11, 26)						
																											Unconscious	23 (17, 42)	Diarrhoea Seizure	22 (20, 25) 24 (9, 79)	Confusion/delirium Unconscious	23 (13, 30) 24 (19, 41)

Notes: * IQR = inter-quartile range.



Section 6 | Update on development of symptoms

children, thirst. Parents of younger children also reported drowsiness and breathing difficulty (usually described as rapid or laboured breathing) at this stage and occasionally diarrhoea.

Three symptoms were fairly frequent: cold extremities (35-47%), limb pain (31 - 63% excluding infants) and abnormal colour (17-21%), usually described as pallor or mottling. Thirst, diarrhoea and breathing difficulty presumably also reflect sepsis but were less common.

RASH

The first classic symptom to emerge was rash, although at onset this was sometimes non-specific and only evolved to a petechial and then grossly haemorrhagic rash over a period of hours. Although it was the most common classic feature of disease it was certainly not always present. (see Table 2). In infants a haemorrhagic rash was present in less than half of cases by hospital admission. The rash was also not an early symptom occurring a median of 8 hours after the start of the illness in babies, 9 hours in 1-4 year olds, 14 hours in 5-14 year olds and 19 hours in the 15 and 16 year olds.

Table 2: Age-specific frequency of clinical features of meningococcal disease prior to hospital admission.

	<1 year %	1 to 4 years %	5 to 14 years %	15 to 16 years %
Early features				
Leg pain	5.1	30.6	62.4	53.3
Thirst	3.4	6.4	11.4	12.6
Diarrhoea	9.9	7.8	3.1	5.5
Abnormal colour	20.6	16.8	18.5	19.0
Breathing difficulty	16.2	9.7	7.1	12.1
Cold extremities	44.0	46.7	34.9	44.4
'Classic' features				
Haemorrhagic rash	42.3	64.2	69.8	65.9
Neck pain or stiffness	15.5	28.1	45.9	52.9
Photophobia	24.5	24.1	26.4	35.5
Bulging fontanelle	11.5	n/a	n/a	n/a
Late features				
Confusion or delirium	n/a	42.8	49.4	47.6
Seizure	8.9	12.8	7.8	7.3
Unconscious	7.0	9.1	5.9	15.1

Notes: 1. Percentages given are standardised to UK case-fatality - see text
2. Age-specific data on frequency of other symptoms are available from the authors.

SYMPTOMS OF MENINGITIS

Meningism was more common in older children, about half the children aged over 5 years had symptoms of meningism and half of these had photophobia. These are not reliable signs in children below 5 years of age.

The median time of onset of specific symptoms suggestive of meningitis (neck stiffness, photophobia, bulging fontanelle) was later, around 12-15 hours from illness onset. The very late stage signs (such as unconsciousness, delirium, or seizures) occurred at a median of 15 hours in infants, about 24 hours in older children.

Fig 1. Time course of development of symptoms.

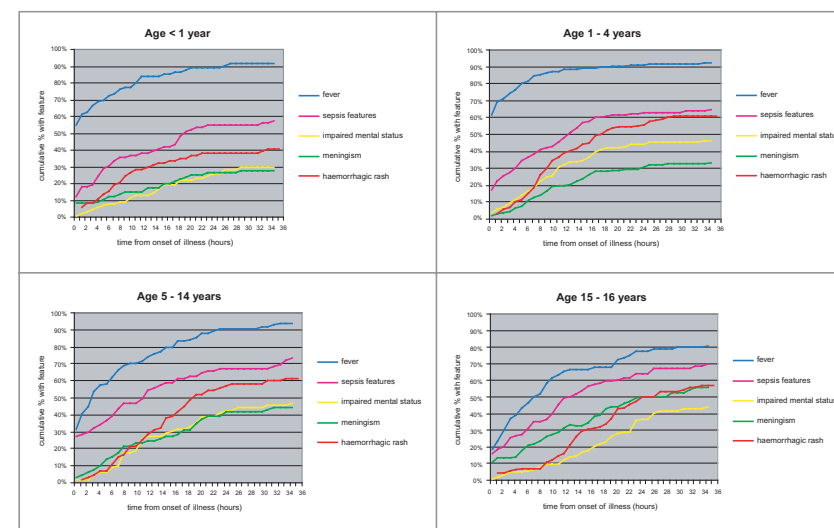
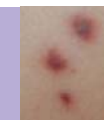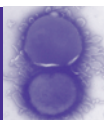


Figure 1 displays graphically by age group the proportion of children developing specific symptoms over the 36 hours from onset of illness. It shows that few children develop new symptoms after 24 hours from onset. The order of progression at all ages is fever, sepsis symptoms and then the classic symptoms of haemorrhagic rash, impaired mental state and meningism. The slower progression of illness in the oldest children is clear; they are also the only age group in which meningism is an earlier and more frequent feature than haemorrhagic rash and impaired consciousness.

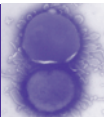


SUMMARY OF IMPORTANT POINTS

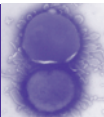
- Most children with meningococcal disease will become ill enough to require hospital admission within 24 hours of the start of their symptoms. This means there is a narrow window for diagnosis and doctors must be aware of the early symptoms of meningococcal infection to maximise their opportunity to make the diagnosis.
- The symptoms children present with vary with increasing age.
- Younger children tend to be brought to hospital earlier in their illness.
- We have identified three important clinical features - limb pain, cold extremities and abnormal colour – which are early sepsis symptoms of meningococcal disease in children and adolescents. We recognise that these symptoms may occur in other febrile illnesses and are not specific to meningococcal disease, but doctors are urged to consider a possible diagnosis of meningococcal disease whenever these symptoms are seen.
- The median times of onset of the early sepsis symptoms were within 7-12 hours. The parents of three-quarters (76.1%) of children identified one or more of these early symptoms before hospital admission. Fewer than 10% of children presented with the classic signs of meningism or impaired consciousness without parents having previously recognised a haemorrhagic rash, or other specific sign of sepsis.
- The rash of meningococcal disease is not an early sign and may not always be present before hospital admission.
- The ‘classic triad’ of symptoms of rash, meningism and impaired consciousness generally occur later in the pre-hospital illness. Do not be reassured by the absence of these ‘classic’ features if you see a child within 12 hours of the start of their illness.

The order of progression at all ages is fever, sepsis symptoms and then the classic symptoms of haemorrhagic rash, impaired mental state and meningism.

1. Booy R, Habibi P, Nadel S, de Munter C, Britto J, Morrison A, Levin M. Reduction in case fatality rate from meningococcal disease associated with improved healthcare delivery. *Archives of Disease in Childhood*. November 2001;85:386-390. <http://adc.bmj.com/cgi/reprint/85/5/386> (accessed 2 Mar 2007).
2. Thorburn K, Baines P, Thomson A, Hart CA. Mortality in severe meningococcal disease. *Archives of Disease in Childhood*. November 2001;85:383-385. <http://adc.bmj.com/cgi/reprint/85/5/382> (accessed 2 Mar 2007).
3. Carcillo JA, Fields AI, Task Force Committee Members. Clinical practice parameters for hemodynamic support of pediatric and neonatal patients in septic shock. *Critical Care Medicine*. 2002; 30:1365-1378. http://www.sccm.org/professional_resources/guidelines/table_of_contents/Documents/ElectronicCopy.pdf (accessed 2 Mar 2007).
4. Pollard AJ, Britto J, Nadel S, DeMunter C, Habibi P, Levin M. Emergency management of meningococcal disease. *Archives of Disease in Childhood*. March 1999;80:290-296 <http://adc.bmj.com/cgi/reprint/80/3/290> (accessed 2 Mar 2007).
5. Welch, S B and Nadel S. Treatment of meningococcal infection. *Archives of Disease in Childhood*. July 2003; 88:608-614 <http://adc.bmj.com/cgi/reprint/88/7/608> (accessed 2 Mar 2007).
6. Ninis N, Phillips C, Bailey L, Pollock JI, Nadel S, Britto J, Maconochie I, Winrow A, Coen PG, Booy R, Levin M. The role of healthcare delivery in the outcome of meningococcal disease in children: case-control study of fatal and non-fatal cases. *British Medical Journal*. June 2005;330:1475. <http://www.bmj.com/cgi/content/full/330/7506/1475> (accessed 2 Mar 2007).
7. Thompson MJ, Ninis N, Perera R, Mayon-White R, Phillips C, Bailey L, Harnden A, Mant D, Levin M. Clinical recognition of meningococcal disease in children and adolescents. *Lancet*. Feb 2006;367(9508):397-403.
8. Health Protection Agency. Enhanced Surveillance of Meningococcal Disease, ESMD graphs, Number of deaths due to meningococcal disease by diagnosis: July 1999 - June 2003. http://www.hpa.org.uk/infections/topics_az/meningo/ESMD_deaths.htm (accessed 2 Mar 2007).
9. Health Protection Agency. Epidemiological data – Meningitis / Meningococcal: Invasive meningococcal infections, England and Wales, by serogroup and age 2000 to 2004. http://www.hpa.org.uk/infections/topics_az/meningo/data_quarters.htm (accessed 2 Mar 2007).
10. Health Protection Agency. Enhanced Surveillance of Meningococcal Disease, National Annual Report: July 2002 - June 2003. http://www.hpa.org.uk/infections/topics_az/meningo/ESMD_annual_report_0203.pdf (accessed 2 Mar 2007).
11. Meningococcal Reference Unit Newsletter, HPA North West Regional Laboratory December 2005 Issue 1, page 3.
12. Cartwright K A, Early management of meningococcal disease. *Infect Dis Clin North Am*. Sept 1999;13(3):661-684.
13. Stiehm ER, Damrosch DS. Factors in the prognosis of meningococcal infection. Review of 63 cases with emphasis on recognition and management of the severely ill patient. *J Pediatr*. Mar 1966;68(3):457-67.
14. Nadel S, Levin M, Habibi P. Treatment of meningococcal disease in childhood. In: Cartwright K, ed. *Meningococcal Disease*. Chichester: John Wiley and Sons, 1995:207-43.
15. Hahne SJ, Gray SJ, Jean-Francois, Aguilera, Crowcroft NS, Nichols T, Kaczmarek EB, Ramsay ME. W135 meningococcal disease in England and Wales associated with Hajj 2000 and 2001. *Lancet*. Feb 2002;359(9306):582-3 <http://www.thelancet.com/journals/lancet/article/PIIS0140673602077164/fulltext> (accessed 2 Mar 2007).
16. Greenwood B. Manson Lecture. Meningococcal meningitis in Africa. *Trans R Soc Trop Med Hyg*. Jul-Aug 1999;93(4):341-53.

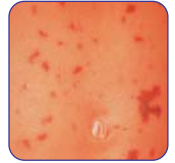


17. Wells LC, Smith JC, Weston VC, Collier J, Rutter N. The child with a non-blanching rash: how likely is meningococcal disease? *Arch Dis Child*. Sep 2001;85(3):218-22. <http://adc.bmj.com/cgi/content/full/85/3/218> (accessed 2 Mar 2007).
18. Goldstein B, Giroir B, Randolph A; International Consensus Conference on Pediatric Sepsis. International pediatric sepsis consensus conference: definitions for sepsis and organ dysfunction in pediatrics. *Pediatr Crit Care Med* Jan 2005;6(1):2-8. [http://www.vritdraugija.lt/index_files/DODS%20kriterijai%20\(PCCM%202005\).pdf](http://www.vritdraugija.lt/index_files/DODS%20kriterijai%20(PCCM%202005).pdf) (accessed 2 Mar 2007).
19. Yung AP, McDonald MI. Early clinical clues to meningococcaemia. *Med J Aust*. Feb 2003;178(3):134-7. http://www.mja.com.au/public/issues/178_03_030203/yun10460_fm.html (accessed 2 Mar 2007).
20. Inkelis SH, O'Leary D, Wang VJ, Malley R, Nicholson MK, Kuppermann N. Extremity pain and refusal to walk in children with invasive meningococcal disease. *Pediatrics*. Jul 2002;110(1 Pt 1):e3. <http://pediatrics.aappublications.org/cgi/reprint/110/1/e3> (accessed 2 Mar 2007).
21. Winrow AP. Abdominal pain as an atypical presentation of meningococcaemia. *J Accid Emerg Med*. May 1999;16(3):227-9.
22. van Deuren M, Brandtzaeg P, van der Meer JW. Update on Meningococcal Disease with Emphasis on Pathogenesis and Clinical Management. *Clin Microbiol Rev*. Jan 2000; 13(1): 144-166. <http://ukpmc.ac.uk/picrender.cgi?tool=pmcentrez&blobtype=pdf&accid=pmcA88937> (accessed 2 Mar 2007).
23. Baldwin LN, Henderson A, Thomas P, Wright M. Acute bacterial meningitis in young adults mistaken for substance abuse. *BMJ*. Mar 1993;306(6880):775-6. <http://ukpmc.ac.uk/picrender.cgi?artid=852050&blobtype=pdf> (accessed 2 Mar 2007).
24. Riordan FA, Thomson AP, Sills JA, Hart CA. Who spots the spots? Diagnosis and treatment of early meningococcal disease in children. *BMJ*. Nov 1996; 313(7067):1255-6. <http://www.bmj.com/cgi/content/full/313/7067/1255> (accessed 2 Mar 2007).
25. Schildkamp RL, Lodder MC, Bijlmer HA, Dankert J, Scholten RJ. Clinical manifestations and course of meningococcal disease in 562 patients. *Scand J Infect Dis*. 1996;28(1):47-51.
26. Barquet N, Domingo P, Cayla JA, Gonzalez J, Rodrigo C, Fernandez-Viladrich P, Moraga-Llop FA, Marco F, Vazquez J, Saez-Nieto JA, Casal J, Canela J, Foz M. Meningococcal disease in a large urban population (Barcelona, 1987-1992): predictors of dismal prognosis. Barcelona Meningococcal Disease Surveillance Group. *Arch Intern Med*. Oct 1999;159(19):2329-40. <http://archinte.ama-assn.org/cgi/content/full/159/19/2329> (accessed 2 Mar 2007).
27. Marzouk O, Thomson AP, Sills JA, Hart CA, Harris F. Features and outcome in meningococcal disease presenting with maculopapular rash. *Arch Dis Child*. Apr 1991;66(4):485-7.
28. Brogan PA, Raffles A. The management of fever and petechiae: making sense of rash decisions. *Arch Dis Child*. Dec 2000;83(6):506-7. <http://adc.bmj.com/cgi/reprint/83/6/506> (accessed 2 Mar 2007).
29. Nielsen HE, Andersen EA, Andersen J, Bottiger B, Christiansen KM, Daugbjerg P, Larsen SO, Lind I, Nir M, Olofsson K. Diagnostic assessment of haemorrhagic rash and fever. *Arch Dis Child*. Aug 2001;85(2):160-5. <http://adc.bmj.com/cgi/content/full/85/2/160> (accessed 2 Mar 2007).
30. Mackway Jones K, Molyneux E, Phillips B, Wieteska S, editors. *Advanced Paediatric Life Support—the Practical Approach*. 3rd ed London: BMJ Books; 2001.
31. Nadel S, Joarder R, Gibson M, Stevens J, Britto J, Habibi P, Owens C. Emergency cranial computed tomography in the management of acute febrile encephalopathy in children. *J Accid Emerg Med*. Nov 1999;16(6):403-6.
32. Hasbun R, Abrahams J, Jekel J, Quagliarello VJ. Computed Tomography of the Head before Lumbar Puncture in Adults with Suspected Meningitis. *N Engl J Med*. Dec 2001;345(24):1727-33. <http://content.nejm.org/cgi/content/full/345/24/1727> (accessed 2 Mar 2007).
33. Shetty AK, Desselle BC, Craver RD, Steele RW. Fatal cerebral herniation after lumbar puncture in a patient with a normal computed tomography scan. *Pediatrics*. Jun 1999;103(6 Pt 1):1284-7. <http://pediatrics.aappublications.org/cgi/reprint/103/6/1284> (accessed 2 Mar 2007).
34. Wylie PA, Stevens D, Drake W 3rd, Stuart J, Cartwright K. Epidemiology and clinical management of meningococcal disease in west Gloucestershire: retrospective, population based study. *BMJ*. 1997 Sep 27;315(7111):774-9. <http://www.bmj.com/cgi/content/full/315/7111/774> (accessed 2 Mar 2007).
35. Sinclair JF, Skeoch CH, Hallworth D. Prognosis of meningococcal septicaemia. *Lancet*. 1987;2(8549):38.
36. Thomson AP, Sills JA, Hart CA. Validation of the Glasgow Meningococcal Septicemia Prognostic Score: a 10-year retrospective survey. *Crit Care Med*. Jan 1991;19(1):26-30.
37. Davison KL, Andrews N, White JM, Ramsay ME, Crowcroft NS, Rushdy AA, Kaczmarek EB, Monk PN, Stuart JM. Clusters of meningococcal disease in school and preschool settings in England and Wales: what is the risk? *Arch Dis Child*. Mar 2004;89(3):256-60. <http://adc.bmj.com/cgi/content/full/89/3/256> (accessed 2 Mar 2007).
38. HPA Meningococcus Forum. Guidance for public health management of meningococcal disease in the UK. *Updated August 2006*. http://www.hpa.org.uk/infections/topics_az/meningo/meningococcalguidelines.pdf (accessed 2 Mar 2007).
39. Tully J, Viner RM, Coen PG, Stuart JM, Zambon M, Peckham C, Booth C, Klein N, Kaczmarek E, Booy R. Risk and protective factors for meningococcal disease in adolescents: matched cohort study. *BMJ*. Feb 2006;332(7539):445-50. <http://www.bmj.com/cgi/content/full/332/7539/445> (accessed 2 Mar 2007).
40. Pathan N, Faust SN, Levin M. Pathophysiology of meningococcal meningitis and septicaemia. *Arch Dis Child*. Jul 2003;88(7):601-7. Review. <http://adc.bmj.com/cgi/content/full/88/7/601> (accessed 2 Mar 2007).
41. Pathan N, Hemingway CA, Alizadeh AA, Stephens AC, Boldrick JC, Oragui EE, McCabe C, Welch SB, Whitney A, O'Gara P, Nadel S, Relman DA, Harding SE, Levin M. Role of interleukin 6 in myocardial dysfunction of meningococcal septic shock. *Lancet*. Jan 2004;363(9404):203-9.
42. McIntyre P. Should dexamethasone be part of routine therapy of bacterial meningitis in industrialised countries? *Adv Exp Med Biol*. 2005;568:189-97. Review.
43. Riordan FA. Improving promptness of antibiotic treatment in meningococcal disease. *Emerg Med J*. May 2001;18(3):162-3. <http://emj.bmj.com/cgi/content/full/18/3/162> (accessed 2 Mar 2007).
44. Nadel S, De Munter C, Britto J, Levin M, Habib P. Albumin: saint or sinner? *Arch Dis Child*. 1998 Nov;79(5):384-5. <http://adc.bmj.com/cgi/content/full/79/5/384> (accessed 2 Mar 2007).
45. Rivers E, Nguyen B, Havstad S, Ressler J, Muzzin A, Knoblich B, Peterson E, Tomlanovich M; Early Goal-Directed Therapy Collaborative Group. Early goal-directed therapy in the treatment of severe sepsis and septic shock. *N Engl J Med*. 2001 Nov 8;345(19):1368-77. <http://content.nejm.org/cgi/content/full/345/19/1368> (accessed 2 Mar 2007).
46. Stuart JM, Gilmore AB, Ross A, Patterson W, et al. Preventing secondary meningococcal disease in health care workers: recommendations of a working group of the PHLS Meningococcus Forum. *Comm Dis Public Health*. 2001;4:102-105. <http://www.hpa.org.uk/cdph/issues/CDPHVol4/no2/secondary%20meningococcal.pdf> (accessed 2 Mar 2007).
47. CATS Clinical Guideline: Status Epilepticus. November 2005. Children's Acute Transport Service. http://www.cats.nhs.uk/downloads/CATS_status_epilepticus.pdf (accessed 2 Mar 2007).
48. Jones L, Clark J, Riordan FA. Validation of an algorithm for managing children with a non-blanching rash. *Arch Dis Child* 2004;89 Sup 1:A1



Early Management of Meningococcal Disease in Children*

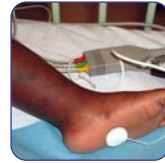5th Edition



Published by

Meningitis Research Foundation

www.meningitis.org



RECOGNITION

May present with predominant SEPTICAEMIA (with shock), MENINGITIS (with raised ICP) or both. Purpuric/petechial non-blanching rash. Rash may be atypical or absent in some cases.

- Call consultant in A&E, Paediatrics, Anaesthesia or Intensive Care
- Initial assessment, looking for features of early shock/raised ICP
- **DO NOT ATTEMPT LUMBAR PUNCTURE**
- IV Cefotaxime (50mg/kg) or Ceftriaxone (80mg/kg)

Estimate of child's weight (1-10 years)

Weight (kg) = 2 x (age in years + 4)

Normal systolic blood pressure = 80 + (age in years x 2)

N.B. Low BP is a pre-terminal sign in children

Conscious Level	Normal Values		
	Age	Respiratory Rate/min	Heart Rate/min
Alert			
Responds to Voice	<1	30-40	110-160
Responds to Pain	1-2	25-35	100-150
Unresponsive	2-5	25-30	95-140
	5-12	20-25	80-120
	>12	15-20	60-100

Observe HR, RR, BP, Perfusion, Conscious Level

Cardiac monitor and pulse oximetry. Take blood for Glucose, FBC, Clotting, U&E, Ca⁺⁺, Mg⁺⁺, PO₄, Blood cultures, Blood Gas (bicarb, base deficit), Cross-match

Inotropes

Dopamine or Dobutamine at 10-20 mcg/kg/min. Make up 3 x weight (kg) mg in 50 ml 5% dextrose and run at 10 ml/hr = 10 mcg/kg/min. (These dilute solutions can be used via a peripheral vein.)

Start Adrenaline via a central line only at 0.1 mcg/kg/min. Make up 300 mcg/kg in 50 ml of normal saline at 1 ml/hour = 0.1 mcg/kg/min.

Intubation (call anaesthetist)

Atropine 20 mcg/kg (max 600 mcg) AND Thiopentone 3-5 mg/kg AND Suxamethonium 2 mg/kg (caution, high potassium) ETT size = age/4 + 4, ETT length (oral) = age/2 + 12 (use cuffed ET tube if possible). Then: morphine (100 mcg/kg) and midazolam (100 mcg/kg) every 30 mins.

Hypoglycaemia (Glucose < 3 mmol/l)

5ml/kg 10% dextrose bolus i.v. and then dextrose infusion at 80% of maintenance requirements over 24 hours.

Correction of metabolic acidosis pH < 7.2

Give half correction NaHCO₃ i.v.

Volume (ml) to give = (0.3 x weight in kg x base deficit + 2) of 8.4%NaHCO₃ over 20 mins, or in neonates, volume (ml) to give = (0.3 x weight in kg x base deficit) of 4.2% NaHCO₃.

If K⁺ < 3.5 mmol/l

Give 0.25 mmol/kg over 30 mins i.v. with ECG monitoring. Caution if anuric.

If total Calcium < 2 mmol/l or ionized Ca⁺⁺ < 1.0

Give 0.1 ml/kg 10% CaCl₂ (0.7 mmol/ml) over 30 mins i.v. (max 10 ml) or 0.3 ml/kg 10% Ca Gluconate (0.22 mmol/ml) over 30 mins (max 20 ml).

If Mg⁺⁺ < 0.75 mmol/l

Give 0.2 ml/kg of 50% MgSO₄ over 30 mins i.v. (max 10 ml).

Prophylaxis of household contacts

Inform Public Health, Give Rifampicin (bd for 2 days)

< 1yr 5 mg/kg • 1-12yrs 10 mg/kg • > 12yrs 600 mg or Ceftriaxone (single im dose)

< 12yrs 125 mg • > 12yrs 250 mg

or Ciprofloxacin as single 500 mg dose (not in children <2 or in pregnancy)

< 12 yrs 250 mg • > 12yrs 500 mg

Diagnosis

LP may be important if the diagnosis or aetiology is in doubt, i.e. when meningitis symptoms predominate and where no rash is present, or in infants with fever without a focus. It must not be performed when there are contraindications (e.g. RICP, shock, coagulopathy). LP should never delay treatment.

Blood Cultures, throat swab, whole blood (EDTA specimen) for PCR. CSF (if available) for culture and PCR. Rapid latex antigen test and aspirations/scrapings from skin showing haemorrhagic rash (if locally useful).

Serology

For suspected cases with no isolate or where PCR does not identify serogroup, clotted blood sample to reference laboratory† (acute within 72 hrs and convalescent 10-28 days after presenting symptoms).

Isolates and PCR samples from hospitals in England, Wales and Northern Ireland (local protocols for PCR services may apply)

†HPA Meningococcal Reference Unit

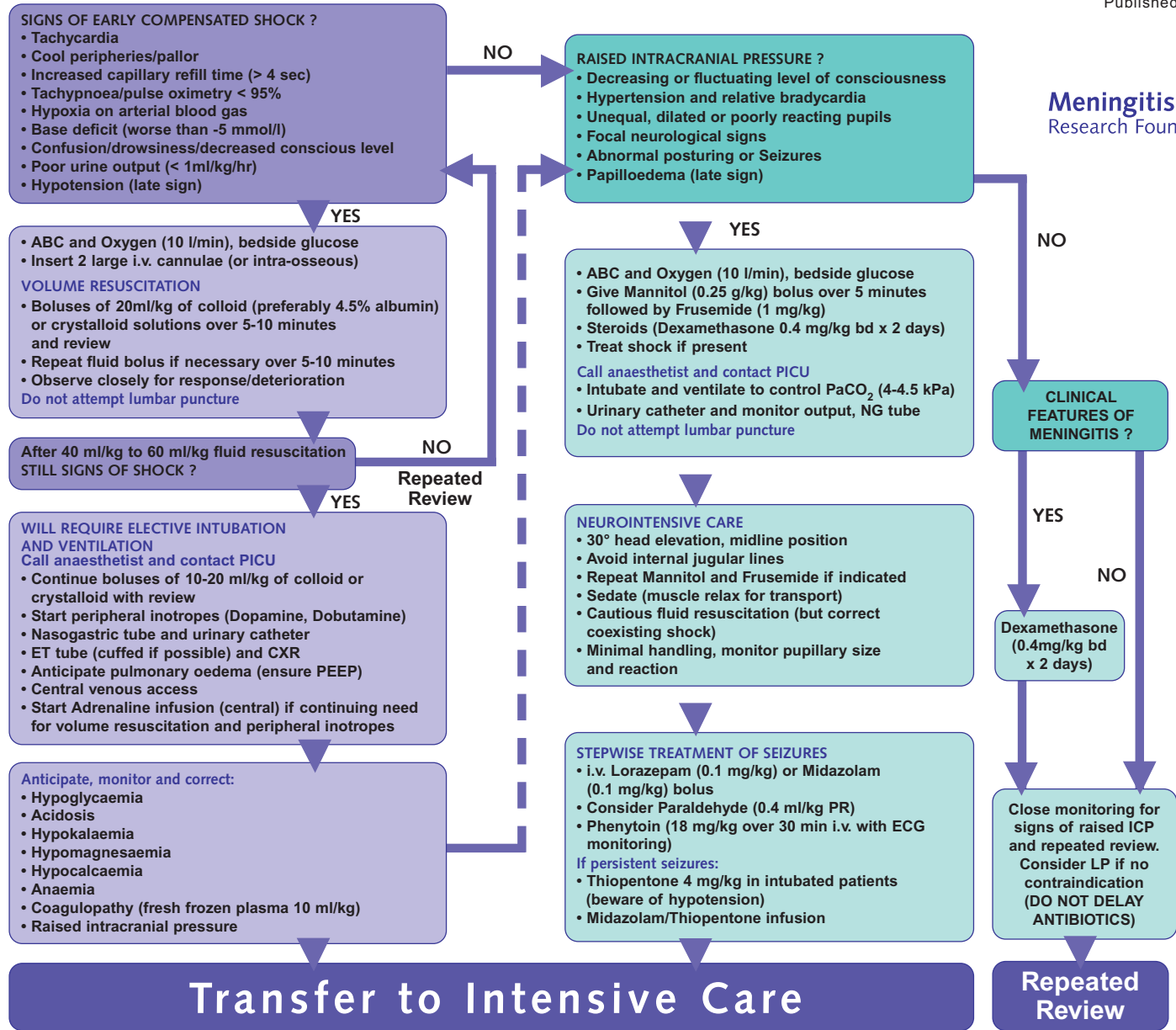
Tel: 0161 276 6757 Fax: 0161 276 5744

Isolates and PCR samples from hospitals in Scotland

†Scottish Meningococcus and Pneumococcus Reference Laboratory
Tel: 0141 201 3836

For further copies of this resource call Meningitis Research Foundation 01454 281811

© A.J. Pollard, S. Nadel, P. Habibi, S.N. Faust, I. Maconochie, N. Mehta, J. Britto, M. Levin (1998), Department of Paediatrics, Imperial College School of Medicine, St Mary's Hospital, London W2
Rev 08/06 (*Arch Dis Child, March 1999; 80: 290-296)



Transfer to Intensive Care

Repeated Review

ACKNOWLEDGEMENTS

Special thanks to Dr Lee Hudson, who supplied some of the case histories, and Dr Fran Ackland, Linda Haines, Kim Brown, and Prof Neil McIntosh, who played an important role in shaping this resource.

We would also like to thank the following people whose comments and input on previous drafts were invaluable: Dr John Alexander, Mrs Kirsten Appleton, Dr Peter Beales, Dr Julia Clark, Prof Tim Coats, Dr Sam Crowe, Dr Haitham El Bashir, Dr Helen Grindulis, Dr Sue Hobbins, Prof Robert Heyderman, Dr Warren Hyer, Dr Fiona Jewkes, Dr Paul Leonard, Dr Roderick MacFaul, Dr Ian Maconochie, Dr Cliff Mann, Dr Nick Mann, Dr Bruce Martin, Dr Nazima Pathan, Dr Mark Peters, Dr Andrew Pollard, Dr Andrew Riordan, Dr Richard Roberts, Dr Michael Ryalls, Dr Andrew Simpson, Dr Bob Taylor, Dr Matthew Thompson , Dr Alistair Thomson, Dr Andy Winrow, Dr Edward Wozniak.

We are particularly grateful to Dr Sue Hobbins, Dr Andrew Newton, Dr Andrew Pollard, and Dr Michael Ryalls for piloting this resource as a learning tool, and the trainee doctors in their tutorial groups who tested it.

This booklet is produced by Meningitis Research Foundation with the help of a Section 64 grant from the Department of Health. It is based on the national study, Healthcare delivery and the outcome of meningococcal disease in children, which was conducted through the Royal College of Paediatrics and Child Health and Imperial College London, and funded by Meningitis Research Foundation with the help of a grant from the Community Fund. The principal investigator was Professor Michael Levin at Imperial College London, and the clinical research fellow was Dr Nelly Ninis.

This resource is part of the Spotting the Sick Child initiative. We would like to thank Dr Ffion Davies for access to photographic material.

Images from Meningitis - Search for a Cure, a Windfall Films Production for Channel Four, are reproduced courtesy of Channel Four Television.

About Meningitis Research Foundation

Meningitis Research Foundation is a national registered charity that funds research into all forms of meningitis and septicaemia, promotes education and awareness, and gives support to people affected.

Based on research and consultation, the Foundation produces guidance notes and algorithms to promote best practice in recognition and treatment of patients with meningitis or septicaemia. Along with the companion e-learning versions of the material in this booklet, and the algorithm overleaf, these include:

- Vital Signs for Frontline Nurses – Early Recognition of Meningitis and Septicaemia
 - Early Management of Suspected Bacterial Meningitis and Meningococcal Septicaemia in Immunocompetent Adults
 - Meningococcal Septicaemia – Identification & Management for Ambulance Personnel
- as well as resources for GPs and for community nurses.

The Foundation also organises targeted scientific and medical conferences.

The charity operates a **Freefone** 24 hour helpline **080 8800 3344** that provides information and offers support and befriending to patients and their families whether they are currently ill, recovering, coping with after effects, or bereaved.

The Foundation produces a range of targeted public information resources that describe the symptoms of meningitis and septicaemia, as well as a DVD for health promotion activities, and written and audio information (mp3 format) in 17 ethnic minority languages. The charity also produces the booklet [Meningitis and Septicaemia – What Happens Next?](#) for people affected by meningitis and / or septicaemia and those who care for them. All of the charity's materials can be obtained free of charge by calling any of our offices, or through our website:

www.meningitis.org

Registered Office:

Midland Way Thornbury Bristol BS35 2BS
Tel 01454 281811

71 Botanic Avenue Belfast BT7 1JL
Tel 028 9032 1283

133 Gilmore Place Edinburgh EH3 9PP
Tel 0131 2283322

Office also in the Republic of Ireland

A charity registered in England & Wales no 1091105,
in Scotland no SC037586 & in Ireland no CHY 12030.
© Meningitis Research Foundation 03/2007


Meningitis
Research Foundation