



Royal College of  
**Paediatrics and Child Health**

*Leading the way in Children's Health*

# **MRCPCH CLINICAL EXAMINATION**

## **Clinical Examination Technique in the short cases**

© Royal College of Paediatrics and Child Health 2004, revised and updated 2010

# Contents

	<b>Page no.</b>
<b>List of Contributors</b>	<b>3</b>
<b>Foreword</b>	<b>4</b>
<b>Introduction to the MRCPCH Clinical examination</b>	<b>5</b>
<b>The short cases</b>	<b>6</b>
<b>Clinical examination technique</b>	<b>8</b>
<b>General appearance</b>	<b>8</b>
<b>Respiratory system</b>	<b>10</b>
<b>Ear, nose and throat</b>	<b>13</b>
<b>Cardiovascular system</b>	<b>14</b>
<b>Abdominal system</b>	<b>19</b>
<b>Nervous system</b>	<b>22</b>
<b>Developmental assessment: Age 0-3 years</b>	<b>29</b>
<b>Endocrine system</b>	<b>30</b>
<b>Locomotor system</b>	<b>32</b>
<b>Skin</b>	<b>35</b>
<b>Diagnostic Imaging</b>	<b>36</b>

## **Compiled and updated by:**

David Barr  
Keith Brownlee  
Gary Butler  
John Evans  
Helen Foster  
John Gibbs  
George Haycock  
Charles Hind  
Philip Holland  
Tom Lissauer  
John Livingston  
P S Low  
Tom Marshall  
John Martin  
Simon Newell  
John Osborne  
John Puntis  
Kenneth Robertson  
Ted Roussounis  
Charles Skeoch  
Janet Thompson  
Tom Turner  
CY Yeung

Examinations Office, Royal College of Paediatrics and Child Health

# Foreword

The MRCPCH Clinical examination has ten stations. Success in the whole examination depends heavily on examination technique. Six of the stations test the candidate's ability to examine children. The candidate is required to examine children, demonstrating good technique, diagnostic ability and judgement. This crucial testing of Clinical examination technique is of central importance in clinical practice.

This short booklet does not aim to present a syllabus for the examination. It sets a level of technique and expertise which is expected of the good candidate. The book is designed around the membership of the Royal College of Paediatrics and Child Health examination, providing guidelines for examiner and candidates. It also describes what is expected in good paediatric clinical examination technique. This, we hope, will be helpful to all senior house officers and other trainees in paediatrics as well as providing help for teachers and trainers.

A valid exam reflects everyday clinical practice. The aim of the membership is to test the candidates ability to deal with these situations. None of us would wish to learn techniques purely for the examination and then discard them in our everyday practice. This makes it essential that in the membership examination, cases are selected appropriately. Candidates are given specific instructions about the patient and what is expected of them in the examination. The criteria used in judging candidates performance is rated against a recognised standard. The standard presented in this book are those of which the examiner and the candidate should be equally aware.

During the Clinical examination, the candidate is taken to see children with a variety of problems. The aim is for the candidate to demonstrate their ability to examine a child using a competent technique, elicit abnormal findings or their absence and discuss the significance of their findings in solving the clinical problem the patient poses.

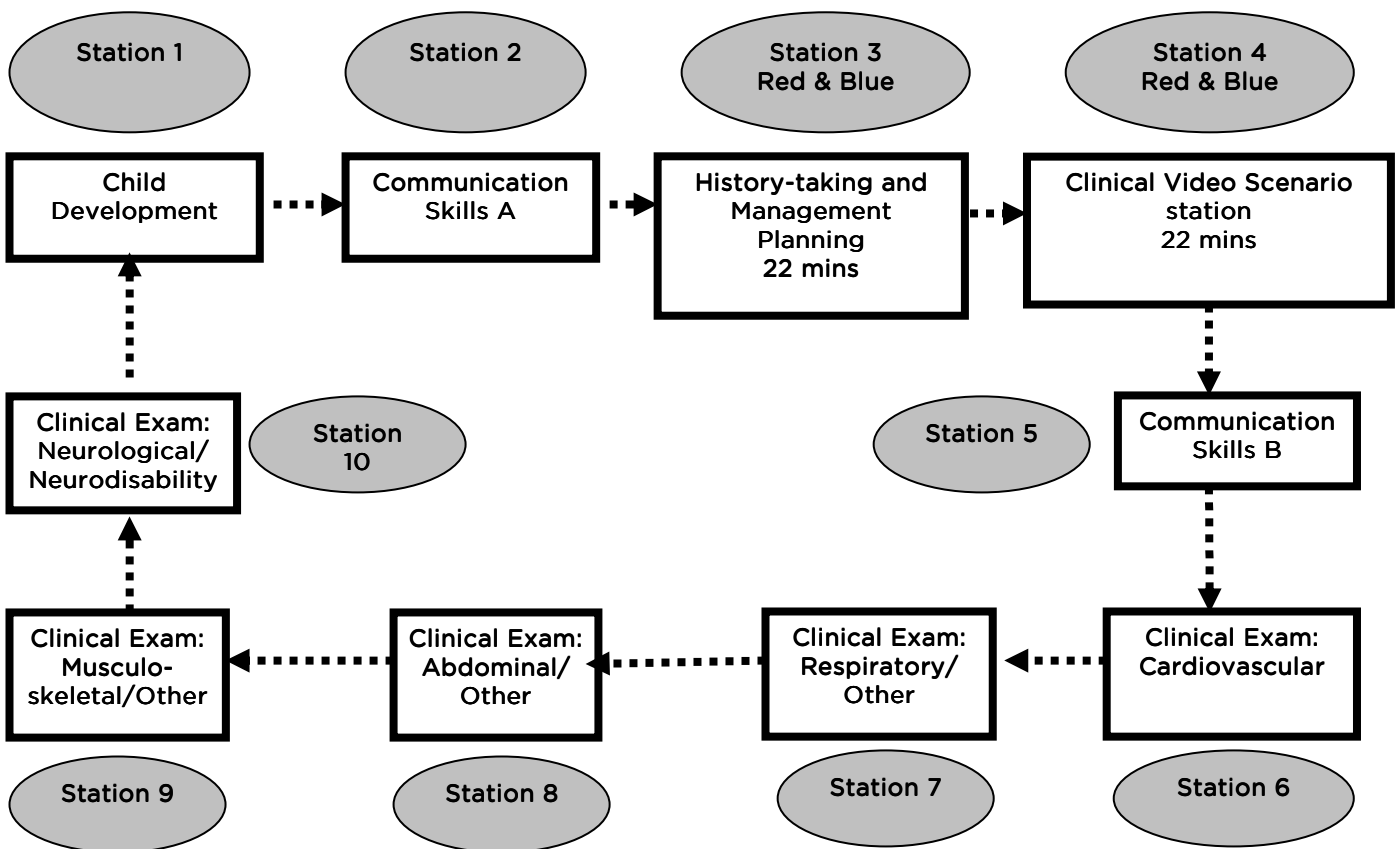
This guide to clinical examination of children was inspired by a similar document prepared by the MRCP (UK) Part 2 Examining Board to whom we are very grateful. The Part 2 Board and colleagues in the paediatric specialties have helped to prepare and refine each section. This second edition may have faults and points which members of the College may wish to criticise. This feedback would be welcome.

Simon J Newell

Vice-President, Training & Assessment

# Introduction to the MRCPCH Clinical Examination

The Clinical examination of the MRCPCH consists of a examination composed of 10 stations for each candidate.



## THE SHORT CASES

- 5 x 9 minute stations:
  - Cardiovascular
  - Respiratory/Other
  - Abdomen/Other
  - Musculoskeletal/Other
  - Neurology
  - A manikin or model may be used in any station
- 1 child per station
- All children seen by examiners to agree on signs and their significance
- Examiners will explain task to candidates
- The precise mix of cases will vary at times
- The good candidate will
  - Show a good approach and system of examination
  - Elicit signs that are present
  - Discuss findings and interpretation with examiners

- Examiners will introduce each Short Case with a very short history, to prompt the candidate to focus on a specific aspect, e.g., “This child has a heart murmur. What do you think is the cause?” “This child has difficulty walking. Please examine her lower limbs and see if you can suggest a diagnosis”.
- In some children, a short clinical scenario will be given. This may avoid the need for the traditional system-based examination approach. The examination is left to the candidate’s discretion. In some children it will be necessary to perform a specific task whilst in others a standard systematic examination will be needed.
- In some short cases, it will be made plain what sort of examination the candidate is required to perform. Three common patterns are used:

Pattern of examination	Example
Full system examination	Would you examine this child’s cardiovascular system
Specific task	Please palpate this child’s precordium and listen to the heart and tell me what you think
Simple observation	Just standing here observing this child on her mother’s knee can you tell me what you notice

- The candidate who has been given a specific task should be expected to perform this. For example, if asked to palpate the abdomen, the candidate should not begin by examining the hands. At the end of the examination of the abdomen, if it was felt that examination of another part of the body was important, the candidate may ask permission to do so or comment on other features which have been noted. Candidates will not be penalised for following instructions.
  - Individual candidates may vary in the exact sequence they adopt when examining a system. For example, it may be prudent to listen to a child's heart while they are quiet. Having found an abnormality on auscultation, the candidate may then wish to examine the femoral pulses, liver etc.
  - The examiners are looking for a systematic, fluid approach. Confidence in the candidate is helpful as it implies that the candidate has regularly examined children.
  - A child friendly approach is expected at all times. Candidates will not be penalised when children become happy or upset during examination, provided this is not the result of the candidate's technique. The candidate's general approach and attitude toward the child and parents is important and will be noted.
  - Cases without abnormal physical signs may be included, with an appropriate introduction, e.g., "This young child was referred from the community clinic. He is 16 months, and is unable to walk. What do you think?"
  - Competence in examination technique, ability to elicit abnormal findings or their absence, and ability to discuss their significance will be assessed.
  - The candidate is expected to observe the features in the next section (General Appearance) when examining any child.
-

# Clinical Examination Technique

## **GENERAL APPEARANCE**

In any system examination the candidate should be expected to make some general observation of the child in more or less detail depending upon the relevance. The candidate may be asked to comment if the presentation of a system examination does not include general observations.

### ***General Health***

The candidate should note whether the child shows any signs of being unwell at the time of the examination.

### ***Dysmorphic features***

Abnormalities of a syndromic or non-syndromic pattern may be noted during system examination or the candidate may be referred back to these observations.

### ***Growth and Nutrition***

Full assessment is not usually possible in the short cases. Candidates should remember that it may be difficult to assess a child's age. The candidate should note obvious abnormalities of growth, stature, nutritional status and obesity and be able to assess pubertal status.

### ***Development***

Neurodevelopmental abnormalities may be noted during examination of other systems.

### ***Hands***

The candidate should be able to identify finger clubbing, abnormalities of the nails, note the colour of the hands and recognise poor perfusion.

**Face**

Inspection should include assessment of colour, cyanosis, anaemia, jaundice and any signs of current illness or dehydration. The candidate should note craniofacial abnormalities.

**General observations**

Candidates may comment upon other features noted in the course of clinical examination. This may include evident clinical features, such as a boy with severe widespread eczema. Often other observations are helpful, eg the presence of a nasogastric tube, an intravenous infusion site, an ankle foot orthosis, an inhaler etc.

---

# RESPIRATORY SYSTEM

## *Inspection*

Aspects which the candidate should be able to quickly inspect include the hands, face, neck, and chest wall. (See also section on General Appearance).

### **Hands**

The candidate should be able to identify finger clubbing and cyanosis and abnormal perfusion.

### **Face & neck**

The candidate should be able to identify cyanosis, evidence of increased work of breathing, cough, stridor or upper airway obstructions, nasal congestion or obstruction and other signs of respiratory illness.

### **Chest wall**

- **Shape** - the candidate should be able to recognise different chest wall shapes, and understand their significance (e.g. increase of AP diameter, Harrison's sulci, kyphoscoliosis, barrel chest or pectus carinatum, pectus excavatum).
- **Movements** - the candidate should be able to measure the rate of respiration, and assess whether accessory muscles of respiration are being used, and chest expansion is normal and symmetrical. The pattern of respiratory movement may be abnormal (e.g. asthma).
- **Skin** - the candidate should be able to recognise associated disease (e.g. eczema), evidence of previous surgery (e.g. thoracotomy, chest drain, Portacath) engorged superficial veins (e.g. SVC obstruction), subcutaneous emphysema.

### **Abdomen**

The candidate should be able to comment on the movement of the abdomen with respiratory effort. Examination may include abdominal palpation (e.g. liver edge).

## ***Palpation***

### **Mediastinum**

The candidate should be able to demonstrate appropriate techniques for assessing the position of the upper and lower mediastinum: tracheal position, chest symmetry and apex beat.

### **Chest wall movement**

The candidate should be able to assess both the extent and the symmetry of movement of the chest wall.

### **Neck and axillae**

The candidate should be able to palpate for cervical and axillary lymphadenopathy.

## ***Percussion***

Percussion may not be helpful in infants and toddlers. The candidate should be able to assess the percussion note over both sides of the chest, and to distinguish resonant / hyper-resonant / dull / stony dull notes.

## ***Auscultation***

Candidates should be able to elicit signs and interpret them taking account of a child's age and the presence of upper respiratory tract secretions. The candidate should be able to distinguish bronchial from vesicular breath sounds.

The candidate should be able to assess the intensity of the breath sounds, and any changes in their timing (e.g. prolonged expiratory phase in obstructive airway disease).

The candidate should be able to identify any added sounds (e.g. crackles, wheezes), and to assess their nature and timing (e.g. the fine end-inspiratory crackles).

The candidate should be able to assess vocal resonance, but only when appropriate.

## ***Additional Points***

### **Sputum pot**

The candidate should be able to draw inferences from the contents of the sputum pot (e.g. copious mucopurulent secretions suggest bronchiectasis).

### **Peak flow rate**

The candidate should be able to measure the peak flow rate, using the appropriate meter and know that the result relates to the child's height.

### **Inhaler technique**

The candidate should be able to assess inhaler technique, and be familiar with standard inhaler devices and their appropriate application.

### **Tracheostomy**

The candidate should recognise a tracheostomy or previous scar and understand why it is present.

## ***Patterns of Abnormalities***

The candidate should be able to recognise and sensibly discuss the pattern of abnormal

signs which suggest the following:

- Consolidation
- Collapse or removal of a lung (or part thereof)
- Pleural effusion
- Pneumothorax
- Airflow obstruction
- Bronchiectasis

## **EAR, NOSE AND THROAT**

The candidate is expected to make a competent examination of the ear, nose and throat and associated lymph nodes. (See also section on General Appearance).

### ***Ears***

The candidate should direct the child's parents to assist in holding the child appropriately while the ears are examined. The auriscope should be held in such a way that movement of the child does not allow injury to the external meatus. Candidates should be able to recognise conditions including otitis externa, ear wax, otitis media, chronic serous otitis media (glue ear), perforated ear drum, grommets.

### ***Nose***

The examination of the nose is simply by inspection and observation. The candidate should know how to examine the anterior nares with an auriscope.

### ***Throat***

Assisted by the parents in the younger child, the candidate should know how to examine a child's posterior pharynx and tonsillar region. In the co-operative child this should be achieved without causing the child to gag. The candidates should recognise conditions such as acute inflammation, tonsillar hypertrophy and congenital abnormalities.

---

# **CARDIOVASCULAR SYSTEM**

## ***Inspection***

The candidates should be able quickly to inspect the hands, face and neck and chest wall. (See also section on General Appearance). The candidate should understand how symptoms and signs relate to age (e.g. poor feeding in the infant with heart failure, variation in pulse and BP). The effects of previous acute cardiovascular illness should be recognised (e.g. septic emboli, neurodevelopmental problems).

## **Hands**

The candidate should be able to identify finger clubbing, cyanosis, abnormalities of peripheral perfusion, the stigmata of endocarditis and congenital hand abnormalities associated with CVS problems.

## **Face and Neck**

The candidate should examine the lips and tongue for cyanosis. The candidate should be able to recognise abnormalities of complexion, (e.g. anaemia, polycythaemia).

## **Jugular Venous Pulse and Hepatomegaly**

The candidate should understand examination of this aspect is very dependant upon a child's age.

The candidate should be able to differentiate arterial from jugular venous pulsation. The candidate should understand abnormalities of the jugular venous pulse in the older child, although these are rare in paediatric practice. The JVP is best seen with the child lying at 45°, with the child's head turned towards the candidate.

In the infant and young child the candidate should routinely examine the abdomen for hepatomegaly.

## **Chest Wall**

The candidate should be able to recognise different chest wall shapes and evidence of previous surgery (e.g. median sternotomy, lateral thoracotomy, pacemaker).

## ***Palpation***

### **Arterial Pulse**

The candidate should be aware of the components of the normal pulse waveform and their origin. The candidate should be familiar with the range of normal heart rate at different ages. A candidate should be able to detect the following pulse abnormalities and appreciate the underlying pathophysiology:

- Sinus tachycardia
- Sinus bradycardia
- Sinus arrhythmia
- Small volume
- Radio-femoral delay or absent femoral pulses
- Collapsing
- Paradoxical pulse

The brachial pulse is suitable for assessment of the pulse at all ages. In younger children and after surgery the radial pulse may mislead. In older children, candidates may palpate the carotid pulse. Femoral pulses are mandatory.

### **Precordium**

The candidate should attempt to locate the apex beat and be able to distinguish:

- Displacement
- Hyperdynamic apex
- Dextrocardia

The candidate should be able to test for and recognise:

- Right ventricular parasternal lift
- Palpable heart sounds
- Cardiac thrill

## **Blood Pressure**

The candidate should be familiar with the technique of measurement of arterial pressure with a conventional sphygmomanometer, if indicated in both upper and lower limbs. The importance of cuff size should be appreciated. Candidates should relate BP to age and have a rough idea of the normal range for age. Phase IV or V recordings would be acceptable as diastolic blood pressure. The candidate should be aware of the potential significance of abnormalities in blood pressure.

Candidates should be aware of the difficulties of obtaining reliable blood pressure measurements in children. They are not expected to know how to use an automated blood pressure device.

## ***Percussion***

Percussion of the cardiac border or area of cardiac dullness adds little to the clinical assessment. Candidates are not expected to include this in routine examination.

## ***Auscultation***

Candidates should remember that the examiners will have agreed the signs that they are expected to elicit, using standards appropriate for the level of competence required.

The candidate should be able to identify normal heart sounds and the common abnormalities thereof.

- First Sounds, loud S1, split S1
- Second Sound, wide expiratory splitting, fixed splitting, single S2, loud component of S2

In addition the candidate should be able to recognise other auscultatory features such as:

- Sinus arrhythmia
- Gallop rhythm
- Heart murmur

- Ejection click
- Opening snap
- Mid systolic click
- Metallic prosthetic sounds
- Pericardial friction rub

The candidate should be familiar with the surface markings of the four valve "areas" and be able to time murmurs to diastole and systole (e.g. mid, late or pansystolic) or continuous. The loudness/intensity of the murmur should be described. The candidate may use a grading system. If appropriate, auscultation should be performed with the child in different positions.

If a murmur is heard, the candidate should also auscultate the neck and the lateral and posterior chest to assess radiation of the murmur. The candidate should be able to differentiate between innocent murmurs and murmurs related to significant valvular lesions.

### ***Additional Points***

A comprehensive examination of the cardiovascular system includes detection of sacral or lower limb oedema in the older child.

If appropriate, the candidate should seek an AV malformation and listen for a bruit.

### ***Patterns of Abnormalities***

The candidate should be able to recognise and discuss the patterns of abnormal signs. Interpretation should embrace other features (e.g. previous surgery, Down's syndrome).

- Innocent murmur
- Ventricular septal defect
- Atrial septal defect
- Pulmonary stenosis/regurgitation
- Fallot's tetralogy
- Patent ductus arteriosus
- Atrio-ventricular septal defects
- Coarctation of the aorta

- Aortic stenosis/regurgitation
  - Mitral stenosis/incompetence
  - Systemic-pulmonary shunt
  - Pulmonary hypertension
  - Pericarditis/pericardial effusion
  - Tricuspid regurgitation
  - Prosthetic valve
-

## **ABDOMINAL SYSTEM**

### ***Inspection***

The candidate should make a quick general assessment and briefly inspect the hands, face, upper limbs, trunk and abdomen. (See also section on General Appearance).

### **Face, limbs and trunk**

The candidate should be able to identify anaemia, jaundice, stigmata of liver disease and should note other features associated with abnormal abdominal findings (e.g. bruising, haemodialysis, shunts).

### **Abdomen**

- **Shape** - The candidate should be able to recognise different shapes of abdomen, and understand their significance, (e.g. symmetry or asymmetry, flatness or distension, prune belly, hernias).
- **Skin** - The candidate should be able to recognise evidence of previous surgery (e.g. herniotomy, laparotomy), monilial infection, bruising and evidence of superficial veins.
- **Movement** - The candidate should be able to recognise abnormal movement with respiration, visible peristalsis, or pulsations.

### ***Palpation***

The candidate should be able to differentiate normal from abnormal findings, and correctly identify the following organs:

- Liver
- Spleen
- Kidneys
- Bladder
- Female genitalia
- Male genitalia (including descent of testes)

Candidates should also mention other signs identified including abdominal masses.

### ***Percussion***

The candidate should be able to percuss in order to estimate the size of an organ (e.g. liver, spleen). The candidate should be able to examine for ascites and able to elicit shifting dullness and a fluid thrill. If necessary, the examiner can be asked to help.

### ***Auscultation***

The candidate should be able to identify:

- Bowel sounds - increased, normal, absent

### ***Additional Points***

Candidates must not perform rectal or vaginal examinations.

Candidates are not expected to examine the external genitalia or perianal region if this is likely to upset a child. In other circumstances, if this is required the candidate will be specifically asked to do this.

The candidate is expected to recognise the following:

- Nasogastric tube
- Gastrostomy
- Continuous ambulatory peritoneal dialysis or other dialysis catheter
- Ileostomy or colostomy
- Nephrostomy/vesicostomy
- Indwelling central venous access device for parenteral nutrition

### ***Patterns of Abnormalities***

The candidate is expected to recognise normal and abnormal clinical signs and to discuss the pattern of signs which suggests a diagnosis.

- Liver disease  
e.g. portal hypertension, cirrhosis, storage disorder, chronic liver disease
- Splenomegaly  
e.g. spherocytosis, thalassaemia, portal hypertension
- Infection  
e.g. viral hepatitis, ascites, glandular fever

- Inflammatory bowel disease  
e.g. Crohn's, ulcerative colitic
  - Myeloproliferative disorders and haematological malignancies  
e.g. leukaemia, lymphoma
  - Renal disease, renal enlargement and its causes  
e.g. polycystic disease, hydronephrosis and renal tumours
  - Therapeutic intervention  
e.g. CAPD, gastrostomy, transplant, subcutaneous infusion
-

## **NERVOUS SYSTEM**

Candidates are expected to recognise the difficulties and different approaches towards neurological examination in the co-operative 12-year-old, the playful toddler and the newborn infant. They should appreciate that often a great deal can be learnt by watching a child walk or kick a football, before reaching for the tendon hammer. An integrated response is expected combining observations of behaviour and movement with findings on traditional neurological examination. The candidate is expected to adapt all examination techniques for the child's age. (See also section on General Appearance).

### ***Cranial Nerves***

The candidate should be able to examine the cranial nerves, and discuss the pattern of abnormal signs.

I. Not likely to be appropriate for examination

II. The candidate should be able to:

- Make a simple assessment of visual acuity.
- Assess vision. The candidate should be able to detect bitemporal hemianopia and homonymous hemianopia in the older child.

### ***Eyes***

Ophthalmoscopy is important but difficult in most children. A systematic approach to examination of the eye should be used. Candidates should attempt fundoscopy, using suitable techniques and recognise the limitation of their findings.

- Comment on red reflex, cornea, iris, pupil and lens.
- Candidates should recognise sunseting of the eyes.
- Assess the optic disc for optic atrophy or papilloedema.
- Assess abnormalities of the retina, including the presence of haemorrhages and abnormal retinal pigmentation.
- Recognise abnormalities of the lens (e.g. cataract) or iris (e.g. heterochromia, coloboma)

**III, IV, VI** The candidate should be able to:

- Make a general assessment of external ocular movements by getting a child to fix on an object and follow it in an H shaped pattern.
- Know how to test the individual oculomotor nerves.
- Examine and classify a squint and competently perform a cover test.
- Examine for nystagmus and describe and discuss any abnormality, classifying the direction of nystagmus.
- Describe and discuss the abnormal eye movements associated with poor vision.

### **The Pupil**

The candidate should be able to examine the direct and consensual response to light and the near reaction, and be able to diagnose and discuss Horner's syndrome, third nerve palsy and congenital abnormalities (e.g. coloboma).

### **V.**

The candidate should be aware of the cutaneous distribution of the three components of the nerve, and the major muscles it innervates. They should be able to demonstrate the corneal response, the jaw jerk, the testing of masseter and temporalis, and cutaneous sensation.

### **VII.**

The candidate should be able to demonstrate and appreciate the difference between an upper motor neurone and a lower motor neurone facial palsy.

The candidate should also be aware of neurological problems associated with facial palsy (e.g. altered taste, hyperacusis, altered lachrymation).

### **VIII.**

The candidate should understand hearing testing and the most appropriate choice of method according to a child's age and neurodevelopmental status. Simple assessment by history is appropriate. They should understand when it is appropriate to perform electrophysiological tests, distraction testing, co-operation testing and full tone audiometry.

The candidate should be able to carry out Rinné's and Weber's tests using a tuning fork.

**IX.**

This nerve will not be tested in the examination setting.

**X.**

The candidate should be able to recognise palatal deviation, and be aware that the palate deviates to the intact side in a unilateral palatal palsy.

**XI.**

The candidate should test the actions of sternomastoid and trapezius.

**XII.**

The tongue is best examined for abnormal movements as it lies at rest in the mouth. The candidate should be able to recognise and discuss:

- A unilateral palsy (ipsilateral wasting fasciculation and deviation to the paralysed side).
- Fasciculation. The examiners will have agreed that this sign is present and sufficiently obvious to be recognisable.

***Higher Cortical Function***

Candidates should be able to make an assessment of high cortical function:

- Speech; fluency, naming capacity, repetition and comprehension
- Orientation
- Memory

Detailed assessment of complex disorders will not form part of the examination. An ability to make a confident approach to the child with learning difficulty is important as is initial assessment of the degree of learning difficulty.

## ***Motor Functions***

The candidate should be able to assess appearance, power, muscle tone, reflexes and function. They should identify dystonia, and recognise involuntary movements. Tics should be identified.

### **Appearance**

The candidate should be able to identify muscle wasting and hypertrophy, fasciculation, movement disorders and secondary disorders (e.g. kyphoscoliosis).

### **Tone**

Candidates should assess muscle tone. In the upper limb, the candidate should include examination of flexor tone at the elbow, and pronator tone at the wrist. In the lower limb, assessment of adductor tone at the hip, extensor tone at the knee, and plantorflexor tone at the ankle should be included. The candidate should be able to elicit spasticity, rigidity and hypotonia and interpret these findings in the light of other observation.

### **Power**

Power should be expressed in terms of function related to the child's age. The candidate should be able to assess movements against gravity and with gravity eliminated. In the older child, a system of classification of power may be applied but this is not necessary.

### **Co-ordination**

The candidate should be able to demonstrate appropriate techniques for assessing coordination in the upper and lower limbs.

## ***Reflexes***

### **Primitive Reflexes**

The candidate should be able to elicit the grasp, rooting, Moro and asymmetric tonic neck reflexes. They should understand the normal pattern of change with age and the implications of their observations.

### **Tendon Jerks**

The candidate should be able to elicit the biceps, supinator, triceps, knee and ankle reflexes, the abdominal responses and the plantar responses.

### ***Sensory Function***

The candidate should be able to demonstrate light-touch, proprioception, vibration sense and pin prick, providing appropriate testing materials are available.

**Light-touch** - The candidate should use cotton-wool and not drag the stimulus along the surface of the skin.

**Proprioception** - The candidate should show understanding of the sensitivity of joint position sense, and be able to elicit upper limb drift with the eyes closed, or a positive Romberg's test.

**Vibration test** - The candidate should be given a suitable (128Hz) tuning fork.

**Pin prick** - The candidates are not expected to perform any procedure which may be painful or uncomfortable to the patient unless specifically invited to do so by the examiner. The candidate must be provided with appropriate, disposable sharps which do not penetrate the skin.

In testing sensation, the candidate should show understanding of:

- The need to move from areas of reduced to normal sensation when testing cutaneous sensitivity.
- The cutaneous distribution of sensory loss more commonly seen in clinical practice (e.g. cord lesion compared with peripheral nerve lesion).

- Sensory abnormalities which suggest non-organic sensory loss.

### ***Patterns of Abnormalities***

Candidates are not necessarily expected to reach a diagnosis in a child with a neurological problem suitable for short case examination. Findings should always be described and the observations related to each other. Commoner patterns of abnormality include:

- Cerebral Palsy
- Hemiplegia/quadruplegia/diplegia
- Primary muscle disorders
- Hereditary motor sensory neuropathies

### ***Cerebellar Function***

The candidate should be able to examine for nystagmus and recognise dysarthria. The candidate should be familiar with the finger-nose and heel-knee-shin tests. Dysdiadochokinesis in the upper limbs may be demonstrated in older children.

The candidates should recognise the unsteady ataxic gait and truncal ataxia. The association with abnormal head control and nystagmus (discussed previously) should be recognised. The candidate should be able to recognise more common conditions (e.g. ataxic Cerebral Palsy, ataxia-telangiectasia and Friedreich's ataxia).

### ***Gait***

Candidates should be able to observe gait abnormalities. They should ask the child to perform tasks which he/she is happy and able to perform. Ideally the child's legs should be visible and socks and shoes may need to be removed. Gait should be described and interpreted in the light of other findings (e.g. waddling gait implies pelvic girdle weakness, an important cause of which is Duchenne Dystrophy).

The candidate should be able to recognise, and sensibly discuss gaits including those associated with:

- Myopathy (waddling)
  - Hemiplegia
  - Spastic diplegia
  - Cerebellar ataxia
  - Painful limb (antalgic gait)
  - Foot drop
  - Trendelenburg gait
-

## **DEVELOPMENTAL ASSESSMENT: AGE 0 – 5 years**

Full developmental assessment is not possible within the time constraints of the Developmental Station. Candidates may be expected to offer a view on a child's neurodevelopmental status at any age. Candidates should be expected to assess development in children between 0-5 years of age. (See also section on General Appearance).

The candidates should assess development in four categories:

- Gross motor - posture and movement
- Fine motor - vision and manipulation
- Speech and language - hearing and speech
- Social

There is no prescribed set of developmental tests. Use of any set of appropriate milestones is acceptable. Within each developmental category it should be possible to define developmental age within 2-3 months before 2 years of age, and within 4-6 months between 2 and 5 years of age.

Primarily the candidate should use information from direct observation of the child. Candidates may use history from the examiner and the parents. The candidate should be proficient in rapid assessment of gross motor and fine motor skills. They should understand the confidence that they should place on their findings.

The candidates should present findings for each developmental category. The estimated developmental age should be supported by evidence of the age appropriate skill which the child can perform and the observation that a child is not able to perform a skill which might be expected of a slightly older child. The candidate should understand that estimated developmental age is unlikely to be the same for all four categories. Interpretation of the developmental assessment should be made with regard to the range of normal findings and in the context of a child's illness or other associated condition. If neurodevelopmental delay is suggested, the candidate should be able to comment on the confidence and significance of this finding. The candidate should be able to discuss appropriate management steps for the child with developmental problems.

## **ENDOCRINE SYSTEM**

### ***Patterns of Abnormalities***

Many of the techniques required to examine the endocrine system have been discussed previously. Candidates are expected to be familiar with a number of specific techniques. In many cases good observation is the key skill. (See also section on General Appearance).

Candidates should be able to examine and comment upon:

- **The thyroid gland and features of thyroid disease**

Candidates should be able to examine the thyroid gland and detect any focal or general abnormalities (e.g. solitary nodules or goitre). They should be aware how to inspect the gland, to observe during swallowing and to palpate from behind the child if possible. Attention should be paid to related structures and tracheal displacement. Candidates should be able to assess overall thyroid status and note the features of dysthyroid eye disease.

- **Growth**

Candidates are expected to be able to assess a child with growth problems. They should assess growth on an appropriate chart which the candidate completes or on which the child's growth measurements have been entered previously. They should demonstrate familiarity with inherited growth patterns, height, length, weight and head circumference and understand growth velocity charts. Candidates are also expected to make a brief assessment of a child's height and weight for age on simple inspection. They should note variations in normal growth and abnormal patterns of growth including those without a primary endocrine cause, hormone deficient states and growth abnormalities associated with recognised syndromes (e.g. Marfan's syndrome, Cornelia de Lange, Turner's syndrome, achondroplasia, Russell Silver syndrome).

- **Pubertal status/genitalia**

Candidates are advised not to examine the genitalia if this would embarrass or upset the child. If appropriate, examination of the female genitalia is by simple

inspection. The male genitalia should be inspected, common abnormalities of the penis recognised and descent of the testes determined.

The candidate should be able to assess pubertal status on simple examination using the Tanner stages. Approximate assessment of testicular volume may be expected but the candidates are not expected to use an orchidometer.

- **The child with diabetes**

The candidate should understand that in most children with diabetes there will not be abnormal findings. They should know how to examine injection sites, note lipoatrophy, lipohypertrophy and be aware of rare complications of diabetes.

- **Adreno-cortico insufficiency**

Most children will not have signs. Candidates should recognise the features of hypoadrenalism. They should know to look for pigmentary changes and hypotension in Addison's disease. They should be familiar with the features of congenital adrenal hyperplasia.

- **Cushingoid features**

Candidates should be able to recognise the features of primary or secondary excess of corticosteroids. They should comment upon abnormal distribution of fat, striae, hypertension, abnormal facies and adrenal virilism.

- **Obesity**

Candidates should be able to assess simple obesity and specific endocrine disorders (e.g. cushingoid features) and understand the different growth features.

- **Disorders of lipid metabolism**

The candidate will be expected to be aware of the clinical manifestations of abnormal lipid disorders (e.g. premature arcus, xanthelasma and xanthomata).

---

## **LOCOMOTOR SYSTEM**

A clear introduction to the child will be given by the examiners. A structured approach is required to include an assessment of gait, arms, legs and spine (see also section on General Appearance).

### ***General Locomotor Examination***

#### **Gait**

The candidate should be able to differentiate by inspection normality from abnormality, and to characterise abnormal gait patterns (as above).

#### **Joint appearance and movement**

The candidate should be able to differentiate by inspection normality from abnormality and to specify abnormality with respect to swelling, deformity, restricted movement. They should note number and distribution of joints involved in arthritis and understand the significance of these findings. They are expected to be able to examine for associated abnormalities (e.g. psoriasis).

#### **Muscle wasting**

The candidate should be able to differentiate by inspection normal and wasted muscles, to differentiate global from localised wasting, and to specify involved muscles or groups.

#### **Function**

The candidate should be able to assess function with relation to activities of daily living eg mobility and dressing.

### ***Examination of Individual Regions***

The candidate should look, feel, and assess active and passive movement of joints in the examination of hands, elbows, shoulders, spine (cervical, thoracic, lumbar), hips, knees, fet and ankles. The examination should be based on the “look, feel, move”, approach to each joint and function may be assessed (eg gait for hip, knee and foot/ankle). The candidate should be able to:

- Detect abnormalities at these regions.

- Differentiate joint disease from periarticular lesions.
- Define and describe joint abnormality in terms of joint inflammation and/or damage.

The candidate should be able to detect the following signs at non-axial joints: increased warmth, swelling (fluid, soft tissue, bony) fluctuance, joint-line tenderness, coarse crepitus, restriction of movement, stress pain, associated muscle wasting and weakness. The candidate should be able to recognise the associated systemic and multisystem feature of arthritis and connective tissue disease and the need to assess other systems as appropriate.

### ***Patterns of Abnormalities***

The candidate should be able to recognise the clinical presentation, and compose an appropriate differential diagnosis for the following:

- Acute monoarthritis
- Chronic monoarthritis, Oligoarthritis and Polyarthritis
- Scoliosis
- Dislocated hip and developmental dysplasia at the hip
- Contracture syndromes including arthrogyrosis
- Congenital deformities
- Functional gait abnormalities
- The limping child

### ***The role of a musculoskeletal screening examination (pGALS)***

- The pGALS screening examination (paediatric Gait, Arms, Legs and Spine) is simple and quick and helps to localise the site of joint problems.
- pGALS is very useful to identify the pattern of joint involvement especially where symptoms are illocalised
- The pGALS screen findings help to focus a more detailed regional examination (as given above) of the affected joint(s)
- An example of use of the pGALS screen follows;

The examiner at the Musculoskeletal / Other station tells you;

**“This mother has noticed a problem with her child’s walking - please comment on what you see and examine the child appropriately.”**

The child is sitting in a chair and you notice a swollen knee and thigh muscle wasting and tell the examiner this.

*Firstly check the child is not in pain and before requesting the child to walk and observe for limp. Then you request the child to lie supine on the couch and focus your examination on the child’s legs with inspection, palpation, movement of the knee and assess for leg length discrepancy, Baker’s cyst and quadriceps wasting.*

You present your findings at the knee and comment on the gait.

*The examiner asks you to comment on the differential diagnosis - and you list the causes of a swollen joint, comment on red flags to suggest sepsis and any features to suggest chronicity.*

The examiner asks you what further aspects of the clinical assessment are needed.

*You would be expected to comment on what the history (e.g. pointers to infection, reactive arthritis, inflammatory arthritis, and trauma) and be expected also to comment on the importance of a pGALS screen to assess for joint involvement elsewhere which may influence the differential diagnosis.*

The examiner may ask you to perform the pGALS screen or a part of it and may ask what in particular you would be looking for - e.g.

- *cervical spine, symmetrical hip and ankle joint involvement (polyarticular Juvenile Idiopathic Arthritis)*
- *asymmetrical finger and toe joint involvement and psoriasis changes to nails or skin patch (psoriatic arthritis)*
- *thin, small child with arthritis at the hip and knee (inflammatory bowel disease and associated chronic arthritis )*
- *scoliosis (in the child with a leg length discrepancy)*

The examiner asks about your management approach and you discuss investigations and referral pathways.

## **SKIN**

The candidate should be able to:

Identify and describe individual skin lesions, e.g.:

- Macules
- Papules
- Vesicles
- Purpura
- Telangiectasia
- Haemangioma
- Other congenital naevi

Recognise common or important skin disorders, e.g.:

- Eczema
- Psoriasis
- Urticaria
- Cutaneous candidiasis
- Herpes zoster
- Dermatitis herpetiformis

Identify and sensibly discuss the significance of certain skin manifestations, e.g.:

- Erythema nodosum
- Butterfly rash
- Lymphoedema
- Hyperpigmentation
- Hypopigmentation

Identify and sensibly discuss abnormalities of nails or hair:

- Onycholysis
- Nail pitting
- Alopecia

## DIAGNOSTIC IMAGING

Candidates are expected to examine and interpret plain radiographs and other frequently used diagnostic images. This can be used in the context of a child who is being examined or in isolation. Selection of diagnostic images should emphasise the techniques which are used in acute medicine and surgery. Plain radiography is ideal. The candidates are expected to understand other commonly used diagnostic techniques.

The candidate should be able to recognise the type of diagnostic image. They should demonstrate a systematic approach to the interpretation and be aware of the limitations of the different techniques. They should be able to recognise and interpret diagnostic images at the level which one would expect of a new specialist registrar.

<b>SYSTEM</b>	<b>SUITABLE</b>	<b>UNSUITABLE</b>
Respiratory	chest x-ray CT	bronchogram VQ scan
Cardiovascular	chest x-ray	ultrasound catheter studies arteriography
Abdominal	abdominal x-ray	ultrasound
Renal	abdominal x-ray DMSA/Mag 3 MCUG CT/MR	ultrasound intra-operative techniques IVU
Liver	Hida or equivalent abdominal x-ray	ultrasound ERCP
Gastrointestinal	abdominal x-ray contrast swallow/meal contrast enema isotope Meckel's scan	endoscope radiology isotope studies
Neurology	CT/MR skull x-ray neonatal brain ultrasound	contrast myelography arteriography isotope studies
Bones and joints	plain radiology isotope bone scan	arthrography ultrasound bone age